

## Radiographic visualization of the metacarpus and phalanges in the impala (*Aepyceros melampus*)

Mohamed Mostafa<sup>1\*</sup>, Lee Martin Koma<sup>2</sup>, and Osman Ssengoba<sup>3</sup>

<sup>1</sup>Department of Veterinary Surgery, Anaesthesiology and Radiology, Faculty of Veterinary Medicine, Cairo University, Giza, Egypt

<sup>2</sup>Department of Veterinary Surgery and Reproduction

<sup>3</sup>Department of Veterinary Anatomy, Faculty of Veterinary Medicine, Makerere University, Kampala, Uganda

---

**MOSTAFA, M., L. M. KOMA, O. SSENGOBA: Radiographic visualization of the metacarpus and phalanges in the impala (*Aepyceros melampus*). Vet. arhiv 76, 75-83, 2006.**

### ABSTRACT

Radiographic and anatomic studies of the metacarpus and phalanges were evaluated in 10 thoracic limbs of the impala (*Aepyceros melampus*). The metacarpi and phalanges appeared strong and smaller in both size and mass. The fused Mc3/4 appeared longer, rounded, smoother and had a flat palmar surface. The small metacarpal bones (Mc2 and Mc5) were developed and situated on the palmar aspects of the fused Mc3/4. Impala have two digits; each digit has three phalanges (ph I, ph II, ph III) and three sesamoid bones. The two proximal sesamoid bones were elongated. The distal sesamoid bone was quadrilateral in shape. Ph I and p II were much shorter and slimmer. ph III was uniquely triangular in shape. Impala possess a radiographic peculiarity; in the latero-medial radiographic view the dorsal cortex of fused Mc3/4 was thicker than the palmar. The distal epiphysis appeared rounded. The lateral and medial digits were superimposed. In the dorso-palmar view, ph I, ph II, and ph III appeared symmetrical. The proximal and distal sesamoid bones were superimposed. ph III was triangular, with numerous vascular channels. The slim, graceful legs of the impala with narrow and shorter distal segments and reduced weight of the metacarpus and phalanges may represent a distinctive structural modification necessary to facilitate the speedy movement of the impala.

**Key words:** radiology, anatomy, metacarpus, phalanges, impala

---

### Introduction

Impala (*Aepyceros melampus*) belong to the family of antelope, the common name applied to large groups of hollow horned ruminants belonging to the same family (Bovidae)

---

\* Contact address:

Prof. M. B. Mostafa, Department of Veterinary Surgery Anaesthesiology and Radiology, Faculty of Veterinary Medicine, Cairo University, P.O. Box: 12211 Giza, Egypt, Phone: +201 0365 7716; Fax: +202 572 5240; E-mail: mostafa1955ug@yahoo.com

as cattle, goats and sheep (BOITANI and BARTOLI, 1986). Traumatic surgical conditions are commonly encountered in non-domestic animals such as overgrowth claw, abrasions, digital paralysis, contusion, penetrating wounds, claw evulsion and cracks (FOWLER, 1989). The morphologic and radiographic evaluation of the limbs in domestic animals have been extensively studied, in equines (GETTY, 1975; PARK and LEBEL, 1987) and in cattle (ALLEN, 1999). Understanding the normal anatomy of the distal limb and claw in the impala will assist in the management of surgical conditions among this species.

Radiographic evaluation of the distal limb in the impala has not yet been studied. Therefore, the object of this study was to document and compare the morphologic and radiographic anatomy of the foot of the impala with those of domestic animals.

### **Materials and methods**

Ten right thoracic limbs from five impalas (*Aepyceros melampus*) were collected from the Mburu National Park in Western Uganda and were examined. The limbs were disarticulated at their carpi at post-mortem. Lateromedial (LM) and dorsopalmar (DP) radiographic views were made. The radiographic projection factors were 55-56 kvp, 10 mAs and 80 cm FFD.

Specimens for morphologic studies were prepared by carefully dissecting the skin, subcutis and tendons in order to expose the bones. The periosteum was then scraped and the bones immersed in 0.1% caustic soda before leaving to dry.

### **Results**

Anatomical studies showed that the large metacarpal bone (Mc) consists of a fused Mc3 and Mc4. The fused (Mc) was smooth and rounded dorsolaterally (Fig. 1). The palmar surface was flat and increased in width distally. The palmar surface of the fused (Mc) has small metacarpal bones (Mc2 and Mc5). The second and fifth small metacarpal bones were well developed and originated from the palmar aspects of the fused Mc3/4. The shaft of the small metacarpal bones appeared as thin strips. The lateral (Mc5) is longer and starts a few mm from the proximal articular extremity. The medial (Mc2) was attached about 2 cm from the proximal articular extremity (Fig. 2). The proximal extremity of the fused Mc3/4 has three smooth articular surfaces, medial, lateral and central for articulation with the carpal bones. There was a central rectangular groove contain a nutrient foramen (Fig. 3) which opens palmarly.

The distal extremity of the fused Mc3/4 consisted of two symmetrical condyle separated by a deep intercondylar groove (Fig. 4). Each condyle was divided into medial smooth elevated and lateral lower by a smooth sagittal ridge.



Fig. 1. Skeleton of the metacarpus and phalanges in the impala (dorsal aspect): Mc: fused Mc3/4; ph I first phalanx; ph II second phalanx; ph III third phalanx

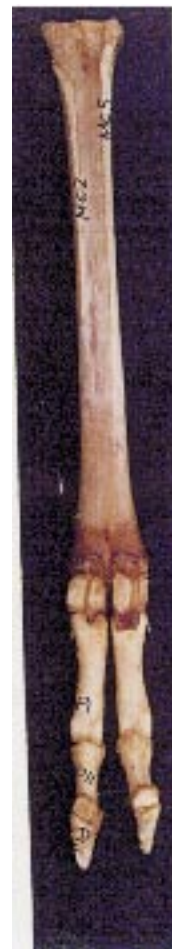

Fig. 2. Skeleton of the metacarpus and phalanges in the impala (palmar aspect); Mc2: second small metacarpal bone; Mc5: fifth small metacarpal bone; the lateral (Mc5) starts a few mm from the proximal extremity, and the medial (Mc5) is attached about 2 cm from the proximal extremity

Impala have two digits, each digit comprising three phalanges (ph I, ph II, ph III) and three sesamoid bones. The proximal sesamoids are four in number, two for each digit. They were situated palmar to the distal end of the fused Mc3/4. The articular surfaces for

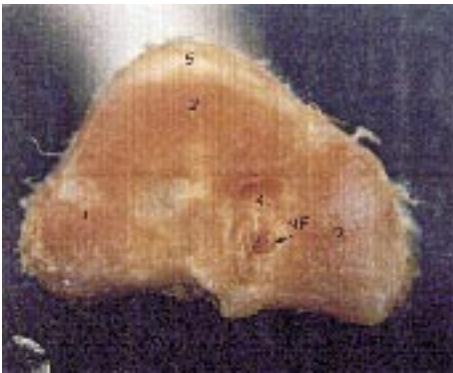

Fig. 3. Proximal extremity of the fused Mc3/4 had three parts of articular surface: 1-medial; 2-central; 3-lateral; 4-a rectangular groove containing a nutrient foramen; 5-metacarpal tuberosity

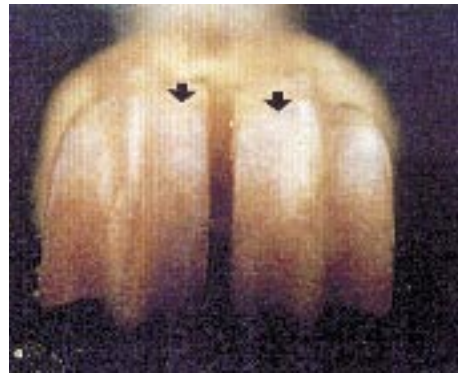

Fig. 4. Distal extremity of the fused Mc3/4 comprises two symmetrical condyles separated by a deep intercondylar groove; the medial condyle is smoothly elevated (arrow) while the lateral one is lower

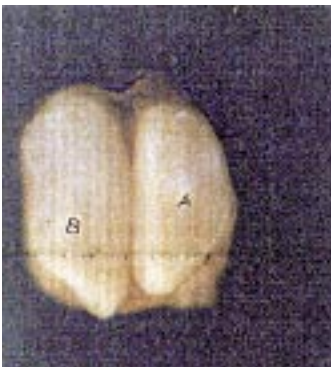

Fig. 5. Distal end of the fused MC3/4 adapted completely to the proximal end of ph I

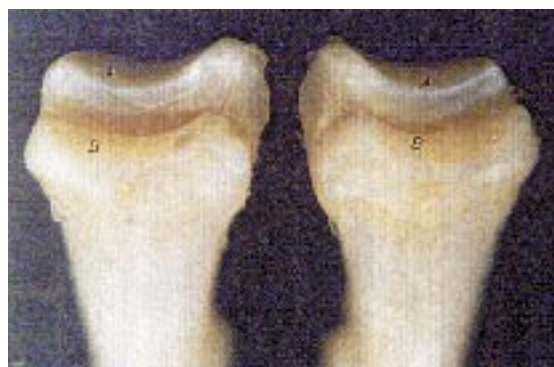

Fig. 6. Proximal articular surface of ph I comprises two parts separated by a sharp, deep sagittal groove. The lateral part is more elevated than the medial, A-lateral articular surface B-medial part of articular surface

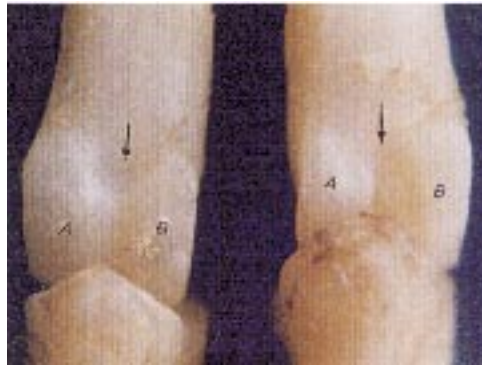

Fig. 7. Distal end of ph I (dorsal aspect) comprises two condyles. The lateral condyle (A) is larger than the medial (B)

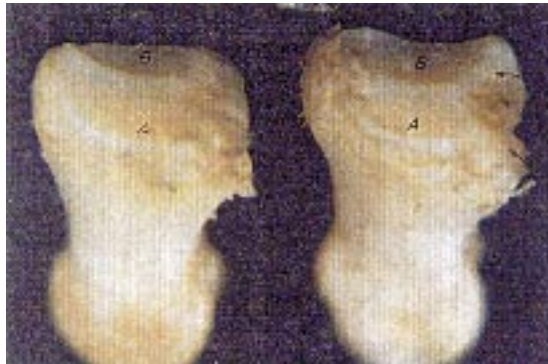

Fig. 8. Proximal extremity of ph II in the impala comprises two parts of smooth articular surface separated by a prominent and sharp sagittal ridge. The lateral part (A) is larger than the medial (B); palmar extremities have two distinct bony prominences (arrow)

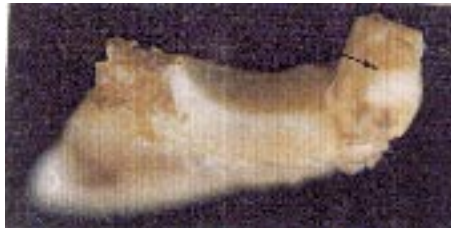

Fig. 9. Distal phalanx in the impala (lateral aspect) is triangular in shape; the articular surface appeared semicircular, (thick), arrow (navicular bone)

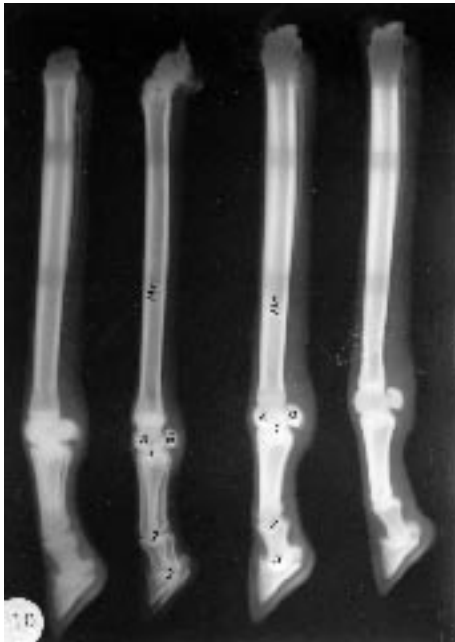

Fig. 10. Latero-medial radiograph of the right metacarpus and phalanges in the impala: Mc: fused Mc3/4 A: distal epiphysis of Mc3/4 B: proximal sesamoid bones, metacarpophalangeal joint (1) proximal interphalangeal joint (2), distal interphalangeal joint (3)

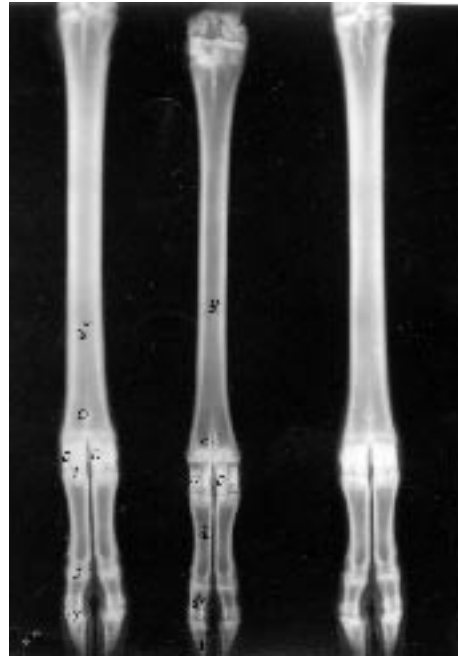


Fig. 11. Dorsopalmar radiograph of the right metacarpus and phalanges in the impala: ph I, ph II, ph III, appeared symmetrical; nutrient foramen (C); superimposed proximal sesamoids (D); metacarpophalangeal joint (1); proximal interphalangeal joint (2) and distal interphalangeal joint (3)

the axial (medial) appeared smooth and concave. The two abaxials (lateral) were shorter and thicker (Fig. 5). The axial sesamoid bones were elongated.

The proximal phalanx appeared three-sided. The shaft was narrow and thicker proximally and distally. The proximal articular surface consisted of two parts separated by a sharp sagittal groove. The lateral part was wider than the medial (Fig. 6.) The proximal end of ph I conformed to the corresponding distal end of the fused MC3/4. The distal extremities of ph I articulated with the proximal extremities of ph II and consisted of two condyles separated by the sagittal groove. The lateral condyle was larger. The distal articular surfaces were extended and extensive in the palmar aspects (Fig. 7) and separated by a notch.

The middle phalanx was slim and much smaller (about one-third of the length of ph I). The proximal articular extremities consisted of two parts separated by a prominent sagittal ridge. The lateral cavity was larger. The proximal palmar extremities had two distinct bony prominence separated by a deep groove for ligament attachment (Fig. 8). The distal extremities were similar in structure to ph I.

The distal phalanx was entirely enclosed by the hoof and was mainly triangular and flat in shape. The axial and abaxial surfaces were wide and smooth proximally, and have numerous vascular foramina distally. There were no semilunar crests or lateral cartilages. The deep flexor tendon was attached to thick tubercles at the solar surface. The proximal articular surfaces appeared semicircular and comprised two parts separated by a prominent ridge. The palmar surfaces contained an articular surface adapted for the distal sesamoid. The coronary or dorsal surface had a rough, pointed eminence for insertion of the common digital extensor tendon (Fig. 9)

There were two distal sesamoid bones, one for each digit, quadrilateral in shape and situated palmar to the junction of the middle and distal phalanx, and dorsal and palmar articular surfaces, proximal and distal borders. The articular surfaces consisted of two parts separated by a central elevated eminence. The dorsal surface articulated with the distal end of ph II and the deep flexor tendon plays over the palmar surface. The proximal border was rough for ligament attachment and the distal border had a facet divided into parts for articulation with the palmar surface of ph III.

Lateromedial radiographic projections revealed that the digits were superimposed. The distal of the fused Mc3/4 appeared completely spherical or rounded. The shape of the metacarpophalangeal; the first and second interphalangeal joints were crescent-shaped or rounded (Fig. 10). The 2<sup>nd</sup> and 5<sup>th</sup> small metacarpal bones articulated with palmar surfaces of the fused Mc3/4. Dorsopalmar views showed that the digits were symmetrical. The proximal and distal sesamoid bones were superimposed on the distal end of the fused Mc3/4 and middle phalanx, respectively. The distal phalanx appeared triangular and had vascular channels (Fig. 11)

## Discussion

Anatomical and radiographic evaluations during this study of the distal limb or foot displayed a unique structural modification in the bones forming the foot. The metacarpi and phalanges in the impala appeared strong, although relatively of smaller size and mass than those of domestic animals. The fused Mc3/4 appeared longer, more rounded and smoother, with flat palmar surfaces. However, in domestic animals the metacarpal bone is semi-cylindrical while ruminants have vascular grooves in the palmar aspect (GETTY, 1975).

Impalas have well developed, small metacarpal bones (Mc2 and Mc5) situated on either side of the palmar surface of the fused Mc3/4. In equines the small metacarpal bones (Mc2 and Mc4) are articulated with the carpal bones, while ruminants have only the fifth or lateral small metacarpal bone, articulated with the palmar surface of the large metacarpal bones (GETTY, 1975).

Impala have four proximal sesamoid bones, two for each digit. The shape of axial and abaxial sesamoid bones were elongated, while the abaxial sesamoid was shorter and thicker. Contrary to findings in domestic animals the bones are three-sided and pyramidal in shape (GETTY, 1975). The function of the proximal sesamoid bones is to provide stability to the suspensory apparatus as it courses over the palmar/plantar surface of the fetlock (HUBERT et al., 2001). It seems that the structural differences could be attributed to an adaptive premium for the running ability of the impala.

The proximal and middle phalanx in the impala was much smaller, shorter and very slim when compared to those of domestic animals. In addition, ph III was uniquely triangular in shape. Furthermore, the distal sesamoid bones in impala are quadrilateral in shape, while in domestic animals the bone appear shuttle-like in shape (GETTY, 1975). Navicular bone increased the surface area of the coffin joint and reduced the impact of loading the deep flexor tendon away from the centre of the coffin joint (LOVING and JOHNSTON, 1995). Therefore, the findings in this study showed that structures of the foot in impala were reduced in mass, shorter, smaller and narrower compared with domestic animals, a fact which provides evidence about the running ability of this animal. Accordingly, GOODSHIP and BRICH (2001) reported that during equine development there was a reduction in bone of the distal limb in order to decrease the energy required for the changes in momentum that occur in cursorial locomotion.

Impala possess a characteristic radiographic peculiarity of the fused Mc3/4 and phalanges in that the distal epiphysis is completely spherical or rounded and the fused Mc is longer and the dorsal cortex is thicker than the palmar. In equines only the mid-portion of the dorsal cortex of the Mc is thicker (KNELLER, 1998). The distal sesamoid bones in the impala is quadrilateral, while in ruminants it is shorter and thicker (WEAVER, 1969).

In conclusion, the slim graceful legs of the impala, with narrower and shorter distal segments and reduced weight of the metacarpal and phalangeal bones, may represent distinctive structural modifications necessary to facilitate speedy movement in the impala.

## References

- ALLEN, L. A. (1999): The use of post mortem radiography as an aid in diagnosis, documenting and understanding disease in animals. *Veterinary Clinic of North America*. 15, pp. 231-252.



M. Mostafa et al.: Radiographic visualization of the metacarpus and phalanges in the impala (*Aepyceros melampus*)

- BOITANI, L., S. BARTOLI (1986): The Macdonald. Encyclopedia of Mammals. Printed by Officine Grafiche A. Mond. Editore, Verona. pp. 72-74.
- FOWLER, M. E. (1989): Textbook of Zoo and Wild Animal Medicine, 2<sup>nd</sup> ed., W. B. Saunders Company. pp. 550-556.
- GETTY, R. (1975): Sisson and Grossman's Anatomy of the Domestic Animal 5<sup>th</sup> ed., Philadelphia, WB Saunders Company.
- GOODSHIP, A. E., H. L. BRICH (2001): Exercise Effects on the Skeletal Tissues. In: Equine Locomotion (Back, W., H. M. Clyton, Eds.), W. B. Saunders. pp. 227.
- HUBERT, J. D., F. G. LATIMER, R. M. MOORE (2001): Proximal Sesamoid Bone Fractures in Horses. Compendium Continues Education 23, 678-686.
- KNELLER, S. K. (1998): Radiology of the Digits. In: Textbook of Veterinary Diagnostic Radiology. (Thrall, D. E., Ed.), 3<sup>rd</sup> ed., W. B. Saunders Company. pp. 211-218.
- LOVING, N., A. M. JOHNSTON (1995): Veterinary Manual for Performance Horse Blackwell Ltd. pp. 66-68.
- PARK, R. D., J. L. LEBEL (1987): Equine Radiology. In: ADAMS' Lameness in Horses. (Stashak, T. S., Ed.), 4<sup>th</sup> ed. Lea and Febiger, Philadelphia pp. 180-245.
- WEAVER, A. D. (1969): Radiology of Bovine Foot. Br. Vet. J. 125, 573.

Received: 20 December 2004

Accepted: 10 January 2006

---

**MOSTAFA, M., L. M. KOMA, O. SSENGOBA: Radiografski prikaz prsnog prstišta i prstnih članaka impale (*Aepyceros melampus*). Vet. arhiv 76, 75-83, 2006.**

**SAŽETAK**

Radiografska i anatomska istraživanja prstišta i prstnih članaka provedena su na 10 prsnih udova impale (*Aepyceros melampus*). Metakarpalne kosti i falange bile su čvrste i manje s obzirom na veličinu i masu. Spojene Mc3/4 kosti bile su duže, zaobljene, glatke i imale su ravne palmarne površine. Male metakarpalne kosti (Mc2 i Mc5) bile su razvijene i smještene na palmarnoj strani spojenih Mc3/4. Impala ima dva prsta, a svaki prst ima tri falange (fI, fII, fIII) i tri sesamoidne kosti. Dvije proksimalne sesamoidne kosti bile su izdužene. Distalna sesamoidna kost bila je četvrtastog oblika. Proksimalna i srednja falanga bile su mnogo kraće i slabije. Distalna falanga bila je ujednačenog trokutastog oblika. Ustanovljene su određene radiografske osobitosti. U lateromedijalnom radiografskom prikazu, kompakta s dorzalne strane spojenih Mc3/4 bila je deblja od one s palmarne strane. Distalne epifize bile su zaobljene. Medijalni i lateralni prsti bili su smješteni jedni iza drugih. U dorzopalmarnom prikazu fI, fII i fIII bile su simetrične. Proksimalne i distalne sesamoidne kosti oba prsta međusobno su se preklapale. Distalna falanga bila je trokutasta s brojnim krvožilnim kanalčićima. Vitke, gracilne noge impale s uskim i kratkim distalnim dijelovima i smanjenom težinom metakarpusa i falanga predstavljaju svojstvenu građu prilagodenu brzom kretanju impale.

**ključne riječi:** radiologija, anatomija, metakarpus, falange, impala

---

