

Peritoneal tetrathyridiosis in a Siamese cat - a case report

Rifki Haziroglu¹, Eser Ozgencil², Tolga Guvenc^{3*}, Semih Oge⁴,
Recai Tunca⁵, Sait Tong², and Sule Ozsoy¹

¹Department of Pathology, Faculty of Veterinary Medicine, University of Ankara, Diskapi, Ankara, Turkey

²Department of Surgery, Faculty of Veterinary Medicine, University of Ankara, Diskapi, Ankara, Turkey

³Department of Pathology, Faculty of Veterinary Medicine, University of Ondokuzmayis, Kurupelit, Samsun, Turkey

⁴Department of Parasitology, Faculty of Veterinary Medicine, University of Ankara, Diskapi, Ankara, Turkey

⁵Department of Pathology, Faculty of Veterinary Medicine, University of Kafkas, Kars, Turkey

HAZIROGLU, R., E. OZGENCIL, T. GUVENC, S. OGE, R. TUNCA, S. TONG, S. OZSOY: Peritoneal tetrathyridiosis in a Siamese cat. Vet. arhiv 75, 453-458, 2005.

ABSTRACT

Peritoneal tetrathyridiosis in a 6-year-old male Siamese cat is described. Abdominal distension and mass were determined at clinical examination. Parasitic materials, which were free in the peritoneum and attached to the inner body wall and viscera, were viewed macroscopically. Microscopically chronic multiple pyogranulomatous peritonitis, hepatitis and splenitis were observed. Parasites were identified as tetrathyridia of *Mesocestoides* sp., probably *Mesocestoides lineatus*.

Key words: cat, *Mesocestoides*, peritoneal tetrathyridiosis

Introduction

The cestode genus *Mesocestoides* (order *Cyclophyllidea*) is ubiquitous and occurs in metacestode or adult forms in many vertebrate hosts, including carnivores, reptiles, amphibians, murines, avians, nonhuman primates, and humans. Two of the more widely studied species are *Mesocestoides corti*, occurring in North and Central America, and *M. lineatus*, occurring in Europe, Africa, North America and Asia (SOULSBY, 1982; BARKER et al., 1993). The life cycle of *Mesocestoides* sp. is not completely understood and still largely

* Contact address:

Assoc. Prof. Tolga Guvenc, Ondokuzmayis University, Faculty of Veterinary Medicine, Department of Pathology, Kurupelit, Samsun, Turkey, Phone: +90 312 457 60 00/2817; Fax: +90 312 45760 00/2800; E-mail: tguvenc@omu.edu.tr

unknown but it is considered to comprise two metacestode stages and two intermediate hosts. The first stage, metacestode, probably occurs in a coprophagous arthropod, with the second, metacestode, occurring in vertebrates, in this case a Siamese cat. Mammals and reptiles are not infected directly by eggs but must ingest the first stage of metacestode in the first intermediate host (SOULSBY, 1982). The second stage metacestode is known as a tetrathyridium. Tetrathyridia are approximately 1 cm or more long and are found in the serous cavities, particularly the peritoneal cavity, and may rarely cause inflammatory reaction (SOULSBY, 1982; BARKER et al., 1993).

Mesocestoides species can live in a wide range of hosts, but are particularly widespread in carnivores (BARKER et al., 1993). Cats are another host in this infection (SOULSBY, 1982). Other than that, only two case reports related to larval form of this parasite (tetrathyridiosis) have been found in cats (BERG and ANDERSEN, 1982; QUINTAVALLA et al., 1996). No mention was made of peritonitis in those reports. There are no reports about peritoneal tetrathyridiosis, together with pathological and clinical findings, although classical textbooks have recorded peritoneal tetrathyridiosis in cats (SOULSBY, 1982; BARKER et al., 1993).

Materials and methods

A 6-year-old male Siamese cat was admitted to the Department of Surgery with the complaint of anorexia and depression. Abdominal distension and mass were determined at clinical examination of the cat. After ultrasonographic and indirect radiographic examinations, ventral midline experimental laparotomy was performed. Masses involving left kidney and adhesions of the left parietal periton were observed in the left abdominal cavity. Multiple cystic structures were detected as free within the abdominal cavity or adhesive to the peritoneal membranes of visceral organs. The cat was euthanatized at the request of the owner and necropsy was made on the same day. Cystic structures at the abdominal cavity were collected within saline solution for parasitological examination. The samples taken from various organs were fixed in buffered 10% neutral formalin for routine pathological examination. Paraffin sections were cut at 6 µm thickness and stained with hematoxylin and eosin.

Results

At the ultrasonographic examination the mass was echogenic and heterogeneous in appearance, with multifocal echoic cysts (Fig. 1). Radiographic examination in the lateral and ventrodorsal position showed that the small intestines were displaced to the right abdominal wall (Fig. 2). At the tentative laparotomy, more parasitic material was removed from the abdominal cavity, but adherent masses of organisms were covering much of the serosal surface of the intestine, liver, spleen and omentum. These materials

were cysts 1 to 1.5 cm in diameter, some of them included dead parasites surrounded by white calcareous material (Fig. 3a). They were free in the peritoneum and attached to the inner body wall and viscera (liver and spleen). Fibrosis was associated with the infection. Much of the small intestine was encased in a thick fibrotic coat in which many parasites were embedded. The amount of peritoneal fluid was not increased. The larvae could not be positively identified, although they resembled tetrathyridia of *Mesocestoides* sp. The entire intestine was examined in the cat and adult *Mesocestoides* sp. were not found in the lumen.

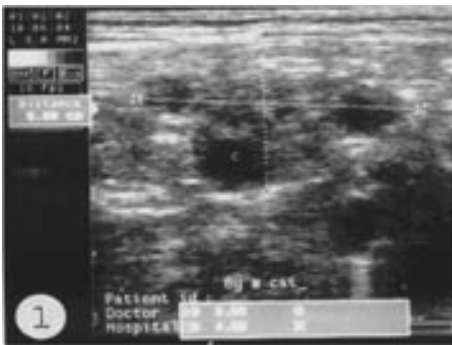


Fig. 1. Ultrasonographic view of the mass in the longitudinal plane of left abdomen. The mass containing multifocal anechoic cystic structures was echogenic in appearance.

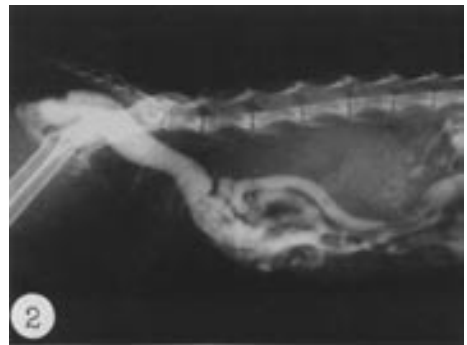

Fig. 2. Indirect radiographic view of the case in a lateral position. Small intestine was displaced to right abdominal wall.

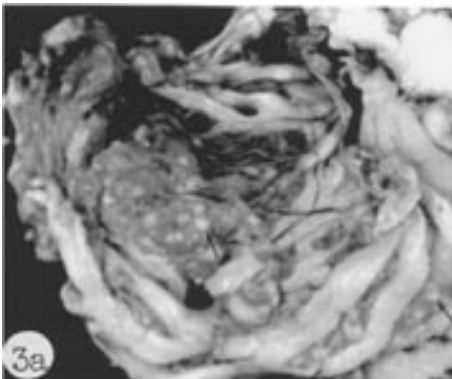


Fig. 3a. Dead parasites surrounded by white material (arrows) and cystic structures 1-1.5 cm in diameter were seen in the abdominal cavity.

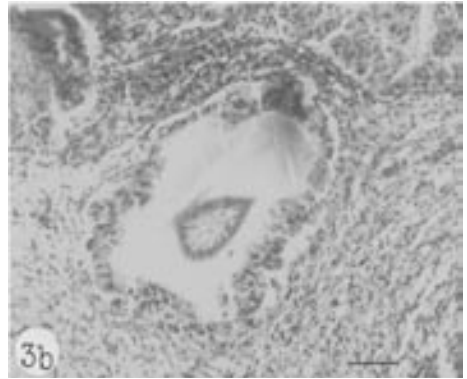


Fig. 3b. Pyogranulomatous inflammation against the slightly degenerated *Mesocestoides* sp. larva. H&E; scale bar = 90 μ m.

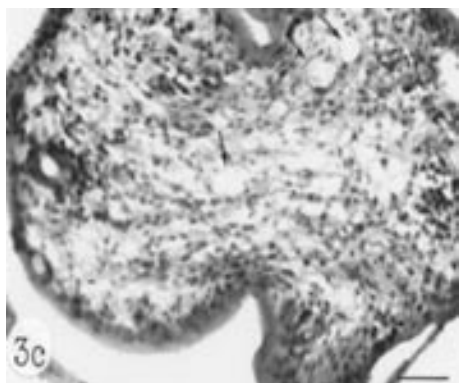


Fig. 3c. *Mesocestoides* sp. larva containing characteristic large empty calcareous corpuscles (arrows) within the mesenchymal network. H&E, scale bar = 30 μ m.




Fig. 3d. Chronic granulomatous inflammation against the degenerated parasitic materials. H&E, scale bar = 30 μ m.

Microscopic examination of the samples taken from inner body wall and viscera revealed generally chronic multiple pyogranulomatous inflammation (Fig. 3b). Individual larvae were different in shape with convoluted borders. Larvae were lined by a thick eosinophilic cuticle. Beneath the cuticle was a single layer of cells. The remaining body of the parasite was composed of a loose mesenchymal network with widely scattered parenchymal and muscle cells. Numerous clear vesicles, namely calcareous corpuscles, round to oval in shape, were observed within the stroma of the parasite (Fig. 3c). Mineralized areas were seen in some of the old lesions. In these lesions, the tegument had a thick eosinophilic smooth-surfaced cuticle. The surrounding interstitium was fibrotic with a moderate number of infiltrating eosinophils and numerous macrophages and lymphocytes (Fig. 3d).

Discussion

Tetrathyridium has been reported in various vertebrate hosts, including wild and domestic birds, snakes, frogs, rodents and dogs (SOULSBY, 1982). Cat is also reported to harbour both the adult tapeworm and intermediate stage at the same time (GURALP, 1974). In this case, we were unable to find adult tapeworms in the intestine, and a feeding experiment was not considered due to technical insufficiency. Identification of the cestode species is based upon the morphology of adult tapeworms harvested from the definitive hosts at necropsy. In practice, however, these feeding experiments are not always possible, successful or feasible.

Mesocestoides lineatus infection in cats occurs in Turkey (GURALP, 1974; DINCER et al., 1980), and incidence of this cestode and its second stage metacestode, *Tetrathyridium*

baillieti (Syn. *T. elongatum*), are 19.4 % and 8.3 %, respectively (DINCER et al., 1980). Peritoneal tetrathyridiosis in cats has been recorded in classical textbooks (SOULSBY, 1982; BARKER et al., 1993) and variously attributed to larval invasion by *Mesocestoides* sp. and *Taenia* sp.

Larval cestode masses in cats (BUERGELT et al., 1984) and primates have been identified as spargana of *Spirometra* sp. However, in this case the proliferative characteristics of the parasite suggested *Mesocestoides* sp. or *Taenia* sp. Histopathological features were not compatible with either parasite. The four basic forms (cysticercus, strobilocercus, coenurus and hydatid cyst) of taeniid metacestodes were considered in differential diagnosis. The cysticercus is a fluid-filled, thin walled, and a single larval tapeworm is invaginated into the cyst. The strobilocercus is late larval development and resembles a tapeworm. Coenuri in tissue sections occur as single or loculated fluid-filled cysts in which many nodular invaginated scolices are present in clusters on the inner wall. The hydatid cyst is a uni- or multilocular structure on the inner terminal membrane of which brood capsules develop. Brood capsules may float free in the cyst fluid (BARKER et al., 1993; CHITWOOD and LICHTENFELS, 1972; BOWMAN and LYNN, 1999). After evaluation of those features in comparison with our case, peritonitis caused by the larval form of *Mesocestoides* sp. was detected in a cat, since the presence of large calcareous corpuscle in the matrix of the larvae and other histological findings are characteristic of *Mesocestoides* sp. (CHITWOOD and LICHTENFELS, 1972; BOWMAN and LYNN, 1999). On the other hand, *Mesocestoides corti* has not been detected in Turkey (GURALP, 1974). For that reason this parasite could be the larval form of *Mesocestoides lineatus*. Alternative identification of *Spirometra* sp. metacestodes was not considered. *Spirometra* sp. does not occur in Turkey and even in instances where *Spirometra* sp. metacestodes are present there is some histological evidence of the parasite, at least numerous tegumental invaginations and irregularly arranged musculature in the plerocercoid must be observed. In this case we could not see such histological findings.

References

- BARKER, I. K., A. VAN DREUMEL, N. PALMER (1993): Infectious and Parasitic Diseases of the Gastrointestinal Tract. In: Pathology of Domestic Animals, 4th ed., vol. 2. (Jubb, K. V. F., P. C. Kennedy, N. Palmer, Eds.). Academic Press. San Diego, New York, Boston, London, Sydney, Tokyo, Toronto. pp. 187-292.
- BERG, C., K. ANDERSEN (1982): Case report of a larval tetrathyridium from the abdominal cavity of a Norwegian cat. Norsk Vet. Tidsskr. 94, 563.
- BOWMAN, D. D., R. C. LYNN (1999): Diagnostic Parasitology. In: Georgis' Parasitology for Veterinarians. 7th ed. (Bowman, D. D. and R. C. Lynn, Eds.). W. B. Saunders Company. Philadelphia. pp. 361-367.

- BUERGELT, C. D., E. C. GREINER, D. F. SENIOR (1984): Proliferative sparganosis in a cat. *J. Parasitol.* 70, 121-125.
- CHITWOOD, M. B., J. R. LICHTENFELS (1972): Identification of parasitic metazoan in tissue sections. *Experimental Parasitol.* 32, 407-519.
- DINCER, S., R. CANTORAY, E. TAŞAN (1980): Elazığ sokak kedilerinde gorulen ic ve dis parazitler ve bunlarin yayilis oranlari uzerinde arařtirmalar. *F. U. Vet. Fak. Derg.* 5, 7-15.
- GURALP, N. (1974): Helmintoloji, Veteriner Fakultesi Yayinlari: 307, Ankara Universitesi Basimevi. pp. 254-257.
- QUINTAVALLA, F., O. PATTACINI, I. BORCIANI, G. MICAGNI, C. NORCIO (1996): Su un caso di tetratiridiosi felina. *Veterinaria* 10, 99-102.
- SOULSBY, E. J. L. (1982): Cestodes. In: *Helminths, Arthropods and Protozoa of Domesticated Animals*. 7th ed., Baillière Tindall. London, Philadelphia, Toronto, Mexico City, Rio De Janeiro, Sydney, Tokyo, Hong Kong. pp. 87-136.

Received: 3. March 2004

Accepted: 7 September 2005

HAZIROGLU, R., E. OZGENCIL, T. GUVENC, S. OGE, R. TUNCA, S. TONG, S. OZSOY: Nalaz tetratiridija u peritonealnoj řupljini sijamske mačke. *Vet. arhiv* 75, 453-458, 2005.

SAŐETAK

Opisana je peritonealna tetratiridioza u šestogodiřnje sijamske mačke. Kod kliničke pretrage ustanovljena je abdominalna distenzija i povećana masa. Makroskopski su utvrđeni slobodni parazitski elementi u trbuřnoj řupljini te priljubljeni na unutarnju stranu trbuřne stijenke i na crijeva. Mikroskopski je ustanovljen kronični multipli piogranulomatozni peritonitis, hepatitis i splenitis. Identificiran je tetratiridij *Mesocestoides*, vjerojatno *Mesocestoides lineatus*.

Ključne riječi: mačka, *Mesocestoides*, peritonealna tetratiridioza
