

Gizzerosine induced histopathological changes in laying hens

**Branka Artuković¹, Željko Grabarević¹, Marina Tišljarić², Andrea Gudan¹,
Mirna Robić³, Petar Džaja⁴, and Nada Granić⁵**

¹Department of General Pathology and Pathological Morphology, Faculty of Veterinary Medicine, University of Zagreb, Zagreb, Croatia

²Poultry Center, Croatian Veterinary Institute, Zagreb, Croatia

³Department of Pathophysiology, Faculty of Veterinary Medicine, University of Zagreb, Zagreb, Croatia

⁴Department of Forensic Veterinary Medicine, Faculty of Veterinary Medicine, University of Zagreb, Zagreb, Croatia

⁵Veterinary Station Dr. Milan Kralj, Metković, Croatia

ARTUKOVIĆ, B., Ž. GRABAREVIĆ, M. TIŠLJAR, A. GUDAN, M. ROBIĆ, P. DŽAJA, N. GRANIĆ: Gizzerosine induced histopathological changes in laying hens. Vet. arhiv 75, 1-13, 2005.

ABSTRACT

Histopathological changes in organs of laying hens challenged with different doses of gizzerosine (2.5; 5; 7.5 and 10 mg/kg b.w. daily during a three-week period) are described. The experiment was performed on 115 hens divided into five groups (K0/n=10/-no treatment, K1/n=21/-treatment with saline, G1/n=21/-2.5 mg/kg b.w. of gizzerosine, G2/n=21/-5 mg/kg b.w., G3/n=21/-7.5 mg/kg b.w.). Gross changes were mainly noticed on gizzards with mild congestion and reversible degenerative changes of the liver and kidneys. Among the histopathological changes (heart, liver, kidney, spleen, lungs, pancreas, brain, duodenum, and proventriculus) in the challenged groups the most prominent were blood vessel lesions (thickening and hyalinisation of the blood vessel walls, perivascular oedema and mononuclear parietal infiltration) especially in the lungs, brain and spleen. Parenchymatous, as well as hydropic and vacuolar degeneration due to hypoxia, were found in all examined tissues. The most prominent changes were in duodenum, where severe inflammation with necrosis was noted, while milder forms were characterized by the vacuolization of duodenal lamina propria. Pancreatic necroses were probably the consequence of direct toxicity of gizzerosine.

Key words: laying hens, gizzerosine, histopathological lesions, subchronic changes

* Contact address:

Dr. Branka Artuković, DVM, Department of General Pathology and Pathological Morphology, Faculty of Veterinary Medicine, University of Zagreb, Heinzelova 55, 10000 Zagreb, Croatia, Phone: +385 1 2390 186; Fax: +385 1 2441 390; E-mail: branka.artukovic@vef.hr

Introduction

Gizzerosine (2-amino-9-(4-imidasolil)-azanonanoic acid) is a toxic substance isolated in 1983 from heated fish meal (OKAZAKI et al., 1983) and synthesised during the same year (MORI et al., 1983). Many authors have described its role in the aetiology of gizzard erosions in broiler chicks (OKAZAKI et al., 1983; MORI et al., 1985; MASAMURA et al., 1985; SUGAHARA et al., 1987a and 1987b; HINO et al., 1987; ITO et al., 1988; SUGAHARA et al., 1988a and 1988b; BARRERA et al., 1991a and 1991b; SUGAHARA et al., 1992a and 1992b; SUGAHARA et al., 1993; SUGAHARA et al., 1995; DIAZ and SUGAHARA, 1995). Gizzerosine acts on histamine (H₂) receptors in the proventriculus and enhances gastric secretion in chicks ten times more than histamine (MASAMURA et al., 1985; SUGAHARA et al., 1987b). It also stimulates cAMP synthesis 1000 times more than histamine (ITO et al., 1988). Literature data on gizzerosine actions on laying hens are rare. TAKUWA et al. (1987) described gizzard erosions in five flocks of laying hens fed with heated fish meal. Along with gastric changes in animals, they described decreased food intake and egg production. KANTAS and DOBOS-KOVACS (1990) described erosions in hens and broilers fed with fish meal. GRABAREVIĆ et al. (1998) described a dose-dependent mild increase in gastric erosions in hens, but without clinical significance. MRLJAK et al. (1999) reported that different gizzerosine doses significantly decreased the concentration of 1.25-dihydroxycholecalciferol in sera of hens. GRANIĆ (1998) studied the influence of different gizzerosine doses on egg production and eggshell quality. Data concerning the changes in other organs caused by gizzerosine in broilers and hens are extremely rare. TIŠLJAR et al. (2002) described histopathological changes in broilers fed with different doses of gizzerosine. Along with changes in gizzards, changes in other organs, especially vacuolisation of cells in lamina propria of duodenum, jejunum, ileum and caecum in animals which received food with 1.15 ppm of gizzerosine are described, and the authors concluded that changes are probably the consequence of cell hypoxia.

Since in the available data we did not find a description of histopathological changes caused by gizzerosine in laying hens, the purpose of this study was to describe gastric and extra-gastric time- and dose-dependent lesions induced by gizzerosine.

Materials and methods

Birds and housing. In the experiment, 115 laying hens of the Lohmann-brown line, 28 weeks old (peak of laying), with an average body mass of 1700 g. were used during the experiment. The animals were weighed at the beginning and at the end of experiment, and no significant changes were recorded. Animals were kept in wire cages, 4 animals per cage, in strictly controlled environmental conditions (automatic air-conditioned windowless room, constant temperature of 24 °C, humidity 60-70%, lighting pattern of 16 h of light and 8 h of dark, without any source of UV) at a poultry farm. Hens were fed with commercial

food TSH "Prerada" Bjelovar containing no fish meal. The ingredients of diet (g./kg diet) were: crude protein 163, crude fibre 80, ash 120, calcium 34.5, phosphorus 8.5, sodium 1.6, chloride 1.4, and moisture 135. Supplied per kg of diet (pre-mix) were vitamins (retinol 10000 IU, cholecalciferol 1500 IU, α -tocopherol 10 IU, riboflavin 5 mg., pantothenic acid 7.5 mg., niacin 30 mg., thiamine 2 mg., cyanocobalamine 12 mcg., choline chloride 300 mg., thiamine 2 mg., folic acid 0.35 mg.), amino acids (arginine 0.80%, cystine and methionine 0.55%, lysine 0.70%, tryptophan 0.15%) and trace mineral mix (manganese 80 mg., iron 30 mg., zinc 50 mg., cooper 3 mg., cobalt 0.10 mg., iodine 0.50 mg., selenium 0.10 mg.).

Experimental protocol. Animals of the same weight were divided into six groups: K0, K1, G1, G2, G3 and G4. K0 group was formed from 10 healthy animals, non-treated, sacrificed in the beginning of the experiment. Other groups were formed from 21 animals in each group which were treated with 6 ml. of saline solutions into the crop perorally by a plastic flexible tube attached on a syringe daily for 21 day. K1 group received only saline, while other groups (G1, G2, G3 and G4) received different doses of gizzerosine dissolved in saline (kindly supplied by Professor Dr. K. Mori, Department of Agricultural Chemistry, University of Tokyo, Japan) as follows: 2.5, 5.0, 7.5 and 10 mg. of gizzerosine/kg. b.w. Each animal from groups G1, G2, G3 and G4 received each day 4.25, 8.5, 12.75 and 17 mg. of gizzerosine, respectively. The solutions were prepared at the beginning of each week of the experiment and stored under refrigerator condition. From the literature it is known that the immunoreactivity of the gizzerosine solution is preserved after 4 months of storage at -20 °C (ROSSELOT et al., 1996) and that the crystalline substance is stable at room temperature (MORI et. al., 1985). Seven animals from each group were sacrificed on days 7, 14 and 21.

Gross findings. After sacrifice, each animal was necropsied and organ lesions were described, with special attention focused on gizzards. Samples of heart, lungs, liver, spleen, kidneys, gizzard and proventriculus, duodenum, pancreas and brain were taken for histopathological examination. Organ samples were fixed in 10% buffered formalin, embedded in paraffin and cut on a microtome in slices 4-5 μ m thick and stained with hematoxylin-eosine (ALLEN, 1994), Sudan III (frozen sections for visualisation of fat, PALLASKE and SCHMIDEL, 1959) and PAS method for glycogen (GAFFNEY, 1994). Depending on the severity of lesions all changes were semi-quantitatively scored (no changes, mild, moderate and severe degree of change), although the present paper primarily describes the histopathological picture, which includes types and frequency of lesions.

Results

Gross findings. No hens perished during the experiment. Gross lesions, except for the gizzards, were minimal and mainly involved mild degenerative changes and congestion

of the liver and kidneys. More prominent lesions were noted in gizzards of gizzerosine-treated animals (discolorations, erosions and ulcerations) compared to control groups. Gizzard lesions have been comprehensively described in a separate paper (GRABAREVIĆ et al., 1998).

Histopathological findings. Histopathological lesions were noted, with the vast majority in the K1, G1, G2 and G3 groups of animals. In the K0 group the lesions were absent, or present sporadically in the mildest form, in individual animals. Thus, the described histopathological lesions, together with their comparative analysis, were noted for the K1, G1, G2 and G3 groups of hens.

Liver. Degenerative reversible lesions were present, from mildest to severest degree, with various distributions in challenged groups and the K1 group. Mild parenchymatous degeneration characterised by granular appearance of the hepatocyte cytoplasm was observed most frequently in the second and third weeks of the experiment in the G2 group, and in the second week in the G1 group. In the remaining groups (except K0) the lesions were observed with smaller but equal frequency. Severe parenchymatous degeneration (cloudy swelling of the hepatocytes) was noted in all animals in the G4 group in the third week, and in a high percentage in the G3 group in the second week, and in G4 in the first week of the experiment. Hydropic and vacuolar degeneration, manifested by cytoplasmic vacuolisation, was of varying intensity. Mild degree (small, dispersed vacuoles in the individual hepatocytes) was the most frequent in gizzerosine-treated animals, particularly in first week in the G3 group, and in the third week in the G4 group. Severe hydropic and vacuolar degeneration (the vast majority of hepatocytes had significant cytoplasmic vacuolisation with disseminated necrotic cells) was sporadic and most prominent in the third week in the G2 group. Fatty change and lymphocytic infiltration was noted sporadically in all the experimental groups (Table 1).

Table 1. The degrees of hepatic reversible degenerative changes

Histopathological lesion	K0	K1	G1	G2	G3	G4
Parenchymatous degeneration	nc	1 st , 2 nd , 3 rd week (ml)	2 nd week (ml)	2 nd , 3 rd week (ml)	nc	3 rd week (se)
Hydropic degeneration	nc	nc	nc	3 rd week (se)	1 st week (ml)	3 rd week (ml)

nc - no change; ml - mild; mo - moderate; se - severe

Kidney. Moderate parenchymatous tubular degeneration, predominantly of the distal tubules, manifested by epithelial swelling and fine granular appearance of cytoplasm was most prominent in the G3 and G4 groups throughout the experimental period and in second and third week in the K1 group. In all challenged animals hydropic and vacuolar degeneration was also noted, but the severe degree characterised by desquamation of

epithelial tubular cells was present in almost all animals in the G3 group in third week, and the G4 group in second and third weeks of the experiment.

Lung. Congestion and mild perivascular oedema (Fig. 1) was noted in all animals, except for the K0 group, in which it was present in 50% of animals. However, the thickening and hyalinisation of the blood vessel walls, except for the G2 group in the first week of experiment, were found in challenged animals exclusively. The frequency of this lesion increased towards to the end of the experiment. Thus, in the third week of the experiment the same lesion was noted in more than two-thirds of animals in groups G3 and G4. Randomised peribronchial and perivascular lymphocytic infiltration was noted in individual animals in each group.

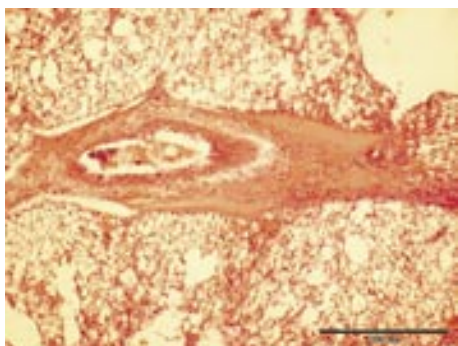


Fig. 1. Perivascular oedema in lungs, group G 4 first week. H&E, scale bar = 200 µm.

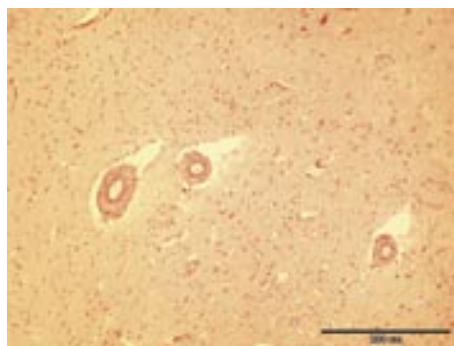


Fig. 2. Perivascular oedema in brain, group G 3 third week. H&E, scale bar = 200 µm.

Heart. Although myocardial perivascular oedema was noted in the K1 group in individual cases, it was much more frequent in challenged animals. It was present in all animals in the G1 group in the second and third weeks of the experiment, and in first week in groups G2 and G3. The same distribution was noted with relation to endomyocardial interstitial oedema (myocytic disarray with prominent and enlarged interfibrillar space filled with pale fluid), which was also more frequent in challenged animals. Contrary to the lung blood vessels, coronary degenerative changes were mostly of mild degree both in the K1 group and challenged animals. However, more severe degenerative changes characterized by hyaline degeneration (pale and oedematous myocytes with partial loss of cross striations) were found only in the first week in group G4. In the same group, in some hens distinctive regions of myocytolysis were noted. In group G1, in the second week one animal had focal myocardial fibrosis.

Spleen. The degenerative changes in blood vessels described above were noted only in challenged animals, and sometimes severe forms of the lesion were characterized by

intraparietal mononuclear infiltration, especially in group G1. In the challenged animals in groups G1 and G2, in some cases focal thrombosis and haemorrhages were seen.

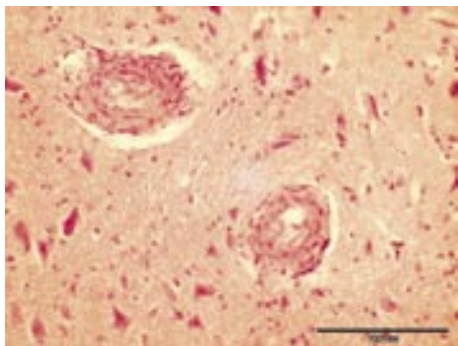


Fig. 3. Degenerative changes in brain artery, group G 4 second week. H&E, scale bar = 100 μ m.

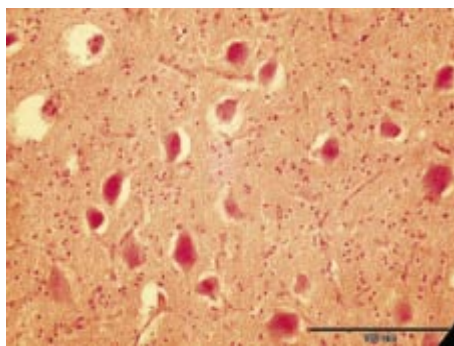


Fig. 4. Gangliocytic shrinkage in cerebellum, group G 4 first week. H&E, scale bar = 100 μ m.

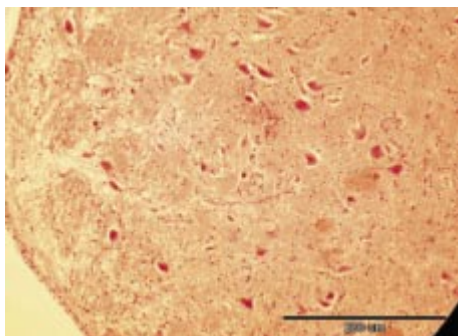


Fig. 5. Demyelination in cerebellum, group G 4, third week. H&E, scale bar = 200 μ m.

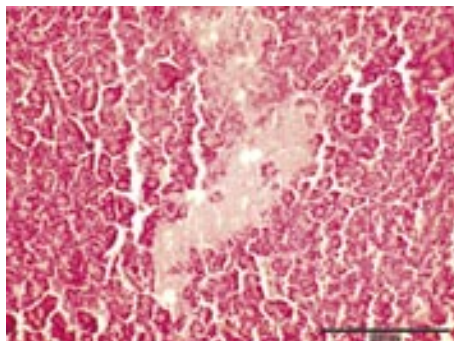


Fig. 6. Focal necroses of the pancreatic acinar tissue, group G 3, second week. H&E, scale bar = 200 μ m.

Brain. Mild perivascular oedema (Fig. 2) was noted in group K1, and severe perivascular oedema in challenged animals. Hyaline degenerative changes of the blood vessels were found almost exclusively in the challenged groups. This was of mild degree in the first and second weeks in group G1, and in the first week in controls. Moderate degenerative changes in blood vessels were more frequent in the second week in group G2, the third week in group G3 and the first week in group G4. Severe degeneration was the most prominent in second (Fig. 3) and third weeks in group G4 and in groups G2 and G3 throughout the duration of experiment. The same lesion distribution may be applied to

the gangliocytic degeneration. Neuronal injury was predominantly of the ischemic type characterised by shrunken and partially vacuolated cell bodies, with pyknotic nuclei and eosinophilic cytoplasm. Mild injury was noted in all animals in the third week in group G3, a large incidence in the second week in group G4 and in the third week in group G2. Severe degeneration was noted in more than half the animals in the first week in group G4 (Fig. 4), only. Together with the mentioned lesions of blood vessels and gangliocytes, individual demyelination, mostly of mild degree, dispersed in all groups, was found (Fig. 5).

Pancreas. In the challenged animals, parenchymatous degeneration of varying degrees, vacuolar degeneration and necrosis of acinar cells, and vacuolar degeneration of islet cells were established. Mild parenchymatous degeneration was noted in all animals in the first week in group G3, a high percentage in the third week in group G2, and in the second week in groups G1 and G3. Severe degeneration was noted in all animals in the third week in group G3, in a high percentage in the first and third weeks in group G1, and in the second week in groups G4 and G2. Vacuolar degeneration of acinar cells was significantly more frequent in challenged animals and most frequent in the third week in group G3 and in the second week in group G2. However, disseminated acinar necroses, i.e. focal pancreolysis, were found only in the challenged groups, predominantly in the second week in group G3 (Fig. 6), in the second and third weeks in group G1, and in the third week in group G2. Langerhans islets lesions (vacuolisation of the individual islet cells), reversible in character, were poorly distributed in all groups.

Duodenum. The only change that was more frequent in controls (K1 group) was oedema of the duodenal lamina propria. However, this change was of mild degree and evident only in a minority of cases. Conversely, inflammatory lesions of various types and varying intensity were more specifically distributed between the groups. In the untreated animals (group K0) there were no changes at all, but the mildest form of inflammation, catarrhal inflammation, was seen in more than half of the animals in first week in group K1, sporadically in the third week in group G1, and in the first week in group G2. More severe inflammatory reaction, such as mild desquamative enteritis, was found in the first week in group K1 and in the third week in group G2, while a moderate degree of inflammation was registered only in the third week in group G2. Typically, a severe degree of the lesion was much more frequent in groups G3 and G4 in the second and third weeks of experiment. Along with these changes, diphteroid inflammation was noted in all challenged groups with high frequency (Fig. 7). An important finding was vacuolisation of the mesenchymal cells of the lamina propria, which was found exclusively in challenged animals. A mild degree was particularly frequent in group G3 (Fig. 8) during all three weeks, while a moderate degree was most prominent in group G2, particularly in first two weeks of experiment. A severe degree was noted sporadically in all the challenged groups. Staining of the vacuoles with Sudan III and PAS methods revealed negative results (Table 2).

Table 2. Degrees of histopathological changes in the duodenum

Histopathological lesion	K0	K1	G1	G2	G3	G4
Oedema of lamina propria	nc	1 st , 2 nd week (ml), 3 rd week (se)	nc	3 rd week (ml)	nc	1 st week (mo), 2 nd week (mo)
Catarrhal inflammation	nc	1 st week (ml)	3 rd week (ml)	1 st week (ml)	nc	nc
Desquamative enteritis	nc	1 st week (ml)	nc	3 rd week (ml) and (mo)	2 nd , 3 rd week (se)	2 nd , 3 rd week (se)
Diphtheroid inflammation	nc	nc	1 st , 2 nd , 3 rd (se)	1 st , 2 nd , 3 rd (se)	1 st , 2 nd , 3 rd (se)	1 st , 2 nd , (mo), 3 rd (se)
Vacuolisation of mesenchymal cells of l. propria	nc	nc	1 st (mo) 2 nd , 3 rd (se)	1 st , 2 nd , 3 rd (mo)	1 st , 2 nd , 3 rd (se)	1 st , 2 nd , 3 rd (mo)

nc - no change; ml - mild; mo - moderate; se - severe

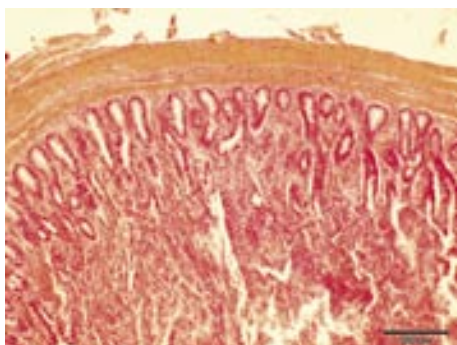


Fig. 7. Diphtheroid duodenitis, group G 4 first week. H&E, scale bar = 200 µm.

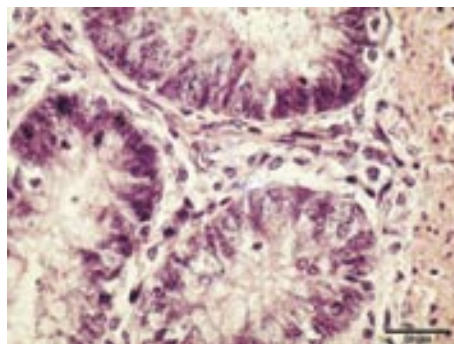


Fig. 8. Vacuolisation of lamina propria in duodenum, group G 3 thrd week. H&E, scale bar = 20 µm.

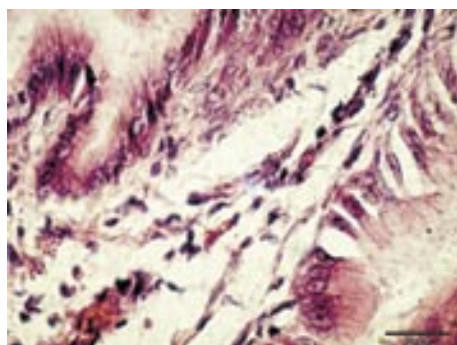


Fig. 9. Vacuolisation of lamina propria in proventriculus. H&E, scale bar = 20 µm.

Proventriculus. Oedema of lamina propria and sub mucosa was the most frequent in the third week in group G4. In almost all groups, except for group K0, distinct vacuoles were visible in lamina propria (Fig. 9), frequently in experimental groups and less frequently in group K1. Vacuolisation of mucosal epithelial cells was the most prominent in the second and third weeks in group G2 and in the first week in group G3. This lesion was also more frequent in challenged animals than in controls, where it was sporadic in the first week. More prominent degrees of epithelial desquamation were most frequent in group G2 in the third week and in group G3 in first and second weeks, while in the remaining challenged and control animals they were similar in degree. In the third week in group G4 villous atrophy was found in some of the hens.

Discussion

There are no literature data on histopathological changes in organs of laying hens induced with gizzerosine. Concerning the liver, reversible degenerations (parenchymatous and hydropic) were noted. A severe degree of parenchymatous degeneration was noted in all animals treated with gizzerosine. As this change evolves primarily as a consequence of insufficient cell ATP production (COOPER, 2002) it can be assumed that the toxic effect of gizzerosine is connected with the disturbance of aerobic cell metabolism. Similar histopathological changes were established in kidneys. Histopathological examination of lungs revealed no significant differences in frequency or type of lesions between individual groups. The only significant difference was thickening and hyalinisation of the pulmonary blood vessels, which was not present in control animals and which gradually increased in a time- and dose-response manner. It can be suggested that the described blood vessel wall thickening leads to decreased tissue perfusion and therefore cell hypoxia. The cause of this may probably be attributed to the effects of gizzerosine on endothelial nitric oxide synthase (eNOS). Namely, HERAK-PERKOVIĆ (2001) showed an absence of immunoreactivity to this enzyme in broilers treated with gizzerosine and histamine. In the same work, she described severe mitochondrial lesions in gizzerosine-challenged animals. Hypoxemia can be the cause of the reversible degenerative changes described in liver and kidney. Changes in heart muscle are very unspecific and do not follow either dose or duration of gizzerosine application. The most prominent lesion in all groups was parenchymatous degeneration and perivascular oedema. In the spleen it is difficult to point out specific lesions which could be connected with gizzerosine action. Nevertheless, it should be mentioned that blood vessel wall degeneration was noted only in hens treated with gizzerosine, although not in all animals, while in control animals that lesion was not present. This is in accordance with described lesions in blood vessels of the lungs. In some degenerated blood vessels cellular mononuclear infiltration was established focally, representing the severe degree of lesion. Histopathological brain changes are of similar character and severity. Again, as with lungs and spleen, thickening of blood vessel walls and degeneration of ganglial cells

in the ischemic injury type were visible in treated animals but not in controls. This was probably the consequence of a severe degree of tissue hypoxia which can be connected with blood vessel lesions. Demyelination was more prominent in cerebellum than in brain and more frequent in groups G2 and G3. This is probably due to the demyelination which accompanies numerous viral and toxic diseases, as well as deficiencies (STORTS, 2001). Pancreatic lesions were mostly degenerative or dyscyclic in character. The finding of acinar necrosis and prominent interstitial oedema was found only in challenged animals. It may be suggested that the necroses are the consequence of the direct toxic effect of gizzerosine. The same effect is already described in the literature for some other toxic substances such as zinc toxicosis in calves and sheep, trichothecene mycotoxicosis of swine, etc. (CULLEN and MACLACHLAN, 2001).

Histopathological proventricular changes indicate a certain level of specificity, although the conclusion arises that they are the also the consequence of vascular disturbances. A significant finding was the appearance of vacuolar dystrophy of lamina propria. Changes are primarily in the connective tissue, although the finding of peripherally located nuclei indicates vacuolisation of cell cytoplasm. As fat and glycogen were eliminated as the vacuolar contents, it should be mentioned that similar changes are frequently the consequence of mitochondrial degeneration, which leads to ATP deficiency, Na-K pump insufficiency and consecutive accumulation of water in the cell (COOPER, 2002). As the mitochondrial function directly depends on oxygen supply and glucose, it can be connected with the described vascular changes. Again, it proves submucosal oedema, which was significantly more frequent in treated animals, especially in group G4. Gizzard lesions were described in detail in the previous, separate publication (GRABAREVIĆ et al., 1998) in which the authors described the most severe lesions in gizzerosine-treated animals after the first week of challenge. Gizzard erosions decreased significantly towards the end of experiment. It should be noted that, contrary to broiler lesions, the changes were of a subclinical character and did not cause death or melena as in broilers, where significantly lower gizzerosine concentration caused the death of animals (SHANE, 1986; SUGAHARA et al., 1987b; SUGAHARA et al., 1988b; WESSLES and POST, 1989; HINRICHSSEN et al., 1997).

Comparing all examined organs, histopathological changes were the most consistent in the duodenum. Namely, described vacuoles in lamina propria were present in most animals in all challenged groups, whereas it was not established in controls. Such vacuolisation was described by TIŠLJAR et al. (2002) in broilers fed with heated fish meal. An additional lesion, characteristic of gizzerosine-treated groups was severe, partially necrotic duodenitis, which was most prominent in group G3. Other forms of inflammation were also more frequent in treated animals than in controls. It would appear that that direct toxic effects of gizzerosine caused severe inflammatory changes, which significantly interfered with normal digestion and resorption in the small intestine.

In conclusion, it should be noted that this experiment demonstrated that stress caused by manipulation of the animals (group K1) caused relatively significant changes in some animals, which in some cases corresponds to gizzerosine-induced lesions. The similarity is probably the consequence of peripheral tissue hypoxia, which could be induced by gizzerosine through its effect on eNOSs and stress, respectively.

References

- ALLEN, T. C. (1994): Hematoxylin and eosin. In: Laboratory methods in histotechnology. (Prophet, E. B., B. Mills, J. B. Arrington, L. H. Sobin, Eds.). American registry of pathology Washington. pp. 53-58.
- BARRERA, E. M., E. O. GONZALES, E. F. CABALLERO (1991a): Efecto en pollo de engordade la adiconde cimetidina a dietas con una harina de pescado causante de Vomito Negro. *Vet. Mex.* XXII, 2, 143-149.
- BARRERA, E. M., E. O. GONZALES, C. L. COELLO (1991b): Evaluacion del contenido de molerosina en dos harinas de pescado mexicanas y su efecto en la presentacion del Vomito negro en pollos. *Vet. Mex.* XXII, 2, 151-158.
- COOPER, B. J. (2002.): Disease at the cellular level. In: Mechanisms of disease. (Slauson, D. O., B. J. Cooper, Eds.) Mosby. Inc. St. Louis. pp. 16-76.
- CULLEN, J. M., N. J. MACLACHLAN (2001): Liver, biliary system, and exocrine pancreas. In: Thompson's Special Veterinary Pathology. (Mc Gavin, M. D., W. W. Carlton, J. F. Zachary, Eds.). Mosby, Inc. St. Louis, London, Philadelphia, Sydney, Toronto. pp. 81-118.
- DIAZ, G. J., M. SUGAHARA (1995): Individual and combined effects of aflatoxin and gizzerosine in broiler chickens. *Br. Poult. Sci.* 36, 729-736.
- GAFFNEY, E. (1994): Carbohydrates. In: Laboratory methods in histotechnology. (Prophet, E. B., B. Mills, J. B. Arrington, L. H. SOBIN, Eds.). American registry of pathology. Washington pp. 149-170.
- GRABAREVIĆ, Ž., P. DŽAJA, V. MRLJAK, B. ARTUKOVIĆ (1998): The effects of gizzerosine in laying hens. *Prax. vet.* 46, 35-41.
- GRANIĆ, N. (1998): Utjecaj toksina gizerozina na zdravlje i nesivost kokoši. Magistarski rad. Veterinarski fakultet, Sveučilište u Zagrebu. Zagreb, Hrvatska.
- HERAK-PERKOVIĆ, V. (2001): Učinci gizerozina i histamina na patomorfološke promjene i prisutnost enzima sintaza dušik (II) oksida u tovnih pilića. Disertacija. Veterinarski fakultet, Sveučilište u Zagrebu. Zagreb, Hrvatska.
- HINO, T., T. NOGUCHI, H. NAITO (1987): Effect of gizzerosine on acid secretion by isolated mucosal cells of chicken proventriculus. *Poult. Sci.* 66, 548-551.
- HINRICHSEN, J. P., M. NEIRA, C. LOPEZ, M. CHIONG, M. P. OCARANZA, R. GALLARDO, M. RUTMAN, J. BLAMEY, S. LAVANDERO (1997): Omeprazole, a specific gastric secretion inhibitor on oxynticopeptic cells, reduces erosion in broiler chicks fed with toxic fish meals. *Comp. Biochem. Physiol.* 117 C, 267-273.

- ITO, Y., H. TERAQ, T. NOGUCHI, H. NAITO (1988): Gizzerosine raises the intracellular cyclic adenosine-3' 5'-monophosphate level in isolated chicken proventriculus. *Poult. Sci.* 67, 1290-1294.
- KANTAS, K., M. DOBOS-KOVACS (1990): Ulcerative gizzard disease in broilers and laying hens. *Magy. Allator. Lapja.* 45, 93-97.
- MASAMURA, T., M. SUGAHARA, T. NOGUCHI, K. MORI, H. NAITO (1985): The effect of gizzerosine, a recently discovered compound in overheated fish meal, on the gastric acid secretion in chicken. *Poult. Sci.* 64, 356-361.
- MORI, K., T. OKAZAKI, T. NOGUCHI, H. NAITO (1983): Synthesis of (\pm) – gizzerosine, an inducer of gizzard erosion in broiler chicks. *Agric. Biol. Chem.* 47, 2131-2132.
- MORI, K., T. SUGAI, Y. MAEDA, T. OKAZAKI, T. NOGUCHI, H. NAITO (1985): Synthesis of the racemic and optically active forms of gizzerosine, the inducer of gizzard erosions in chicks. *Tetrahedron* 41, 5307-5311.
- MRLJAK, V., Ž. GRABAREVIĆ, P. DŽAJA, R. BARIĆ-RAFAJ, J. PERIĆ, B. ARTUKOVIĆ, Z. BIĐIN, S. KIŠ, A. STAVLJENIĆ-RUKAVINA, V. ŠERMAN (1999): Effect of different doses of gizzerosine on the serum 1,25-dihydroxycholecalciferol concentration in laying hens. *Br. Poult. Sci.* 40, 523-528.
- OKAZAKI, T., T. NOGUCHI, K. IGARASHI, Y. SAKAGAMI, H. SETO, K. MORI, H. NAITO, T. MASUMURA, M. SUGAHARA (1983): Gizzerosine, a new toxic substance in fish meal, causes severe gizzard erosion in chicks. *Agric. Biol. Chem.* 47, 2949-2952.
- PALLASKE, G., E. SCHMIDEL (1959): Färbung von Neutralfetten und Lipoiden. In: *Patologisch-Histologische Technik.* (Pallaske G., E. Schmidel, Eds.). Paul Parey in Berlin und Hamburg. Berlin. pp. 84-85.
- SHANE, S. (1986): Gizzerosine, a cause of gizzard erosion in broilers. *Poult. International* 25, 26-27.
- STORTS, R. W., D. L. MONTGOMERY (2001): The nervous system. In: *Thompson's Special Veterinary Pathology.* (Mc Gavin, M. D., W. W. Carlton, J. F. Zachary, Eds.). Mosby, Inc. St. Louis, London, Philadelphia, Sydney, Toronto. pp. 381-450.
- SUGAHARA, M., T. HATTORI, T. NAKAJIMA (1987a): Relationship between growth rate and gastric acid secretion on gizzerosine administration to broiler chicks. *Agric. Biol. Chem.* 51, 3137.
- SUGAHARA, M., T. HATTORI, T. NAKAJIMA (1987b): Lethal toxicity of gizzerosine for broiler chicks. *Agric. Biol. Chem.* 51, 3423-3424.
- SUGAHARA, M., T. HATTORI, T. NAKAJIMA (1988a): Suppression effect of cimetidine, sodium-bicarbonate and magnesium-trisalicilate for gizzard erosion in broiler chicks. *Jpn. J. Zootechn. Sci.* 59, 306-310.
- SUGAHARA, M., T. HATTORI, T. NAKAJIMA (1988b): Effect of synthetic gizzerosine on growth, mortality and gizzard erosion in broiler chicks. *Poult. Sci.* 67, 1580-1584.
- SUGAHARA, M., T. HATTORI, T. NAKAJIMA (1992a): Effect of heating hours and temperature for production of gizzerosine in fishmeal. *Anim. Sci. Technol. (Jpn)* 63, 1028-1031.

- SUGAHARA, M., T. HATTORI, T. NAKAJIMA (1992b): Effect of dietary gizzerosine from fishmeal on mortality and growth of broiler chicks - Anim. Sci. Technol. (Jpn) 63, 1234-1239.
- SUGAHARA, M., T. HATTORI, T. NAKAJIMA (1993): Effect of low concentrations of gizzerosine in broiler chick diets. Jpn. Poult. Sci. 30, 389-395.
- SUGAHARA, M. (1995): Black vomit, gizzard erosion and gizzerosine. W. Poult. Sci. J. 51, 293-306.
- TAKUWA, T., K. FURUKAWA, Y. OKADA, T. SHIROISHI, F. HARA, S. FUJITA. N. NIII, M. GORYO, T. UMEMURA, C. ITAKURA (1987): Gizzard erosion caused by feeding fish meal to laying hens. J. Jpn. Vet. Med. Assoc. 40, 49-53
- TIŠLJAR, M., Ž. GRABAREVIĆ, B. ARTUKOVIĆ, Z. ŠIMEC, P. DŽAJA, Đ. VRANEŠIĆ, A. BAUER, M. TUDJA, V. HERAK-PERKOVIĆ, P. JUNTES, M. POGAČNIK (2002): Gizzerosine-induced histopathological lesions in broiler chicks. Br. Poult. Sci. 43, 28-35.
- ROSSELOT, G., M. LOPEZ-LASTRA, J. P. McMURTRY (1996): Determination of gizzerosine activity in fish meal with a homologous radioimmunoassay. Poult. Sci. 75, 873-880.
- WESSELS, J. P. H., B. J. POST (1989): Effect of heat treatment of fish meals, fines and the addition of lysine as related to gizzard erosion in chickens. J. Sci. Food Agric. 46, 393-406.

Received: 19 December 2003

Accepted: 14 January 2005

ARTUKOVIĆ, B., Ž. GRABAREVIĆ, M. TIŠLJAR, A. GUDAN, M. ROBIĆ, P. DŽAJA, N. GRANIĆ: Patološko-histološke promjene u kokoši nesilica izazvane gizerozinom. Vet. arhiv 75, 1-13, 2005.

SAŽETAK

U radu su opisane patološkohistološke promjene na organima kokoši nesilica koje su dobivale različite doze gizerozina (2,5; 5; 7,5 i 10 mg/kg tjelesne mase dnevno u tijeku tri tjedna). U pokus je bilo uključeno 115 kokoši nesilica podijeljenih u pet skupina. K0/n = 10 - skupina nije dobivala ni fiziološku otopinu niti gizerozin. K1/n = 21 - skupina dobivala je fiziološku otopinu. Skupine G1, G2, G3 i G4 su također imale po 21 životinju i dobivale su različite doze gizerozina otopljenog u fiziološkoj otopini kako slijedi: 2,5; 5; 7,5 i 10 mg/kg tjelesne mase. Makroskopske promjene su uglavnom zabilježene na mišićnom želucu, a utvrđena je i punokrvnost te slabije degenerativne promjene na jetri i bubrežima. Među patološkohistološkim promjenama (srce, jetra, bubrež, slezena, pluća, gušterača, mozak, duodenum i žljezdani želudac) u gizerozinskim skupinama životinja najizraženije su bile promjene na krvnim žilama (zadebljanje i hijalinizacija stijenki krvnih žila, perivaskularni edem te infiltracija stijenke žile mononuklearima) osobito u plućima, slezeni i mozgu. U svim pretraženim tkivima nađena je parenhimska i hidropičnovakuolarna distrofija kao rezultat hipoksije. Najizraženije promjene su bile u duodenumu i očitovale su se jakom upalom, koja je uključivala i nekrotični oblik. Nekroze gušterače su vjerojatno posljedica izravnog toksičnog djelovanja gizerozina.

Ključne riječi: kokoši nesilice, gizerozin, patohistološke promjene, subkronične promjene
