

Comparative efficacy of fine needle aspiration and incisional biopsies in the diagnosis of bovine actinomycosis

Nawab Nashiruddullah¹, Mohammed Maqbool Darzi^{1*}, Shayaib Ahmed Kamil¹, Masood Salim Mir¹, and Faizullah Peer²

¹Division of Veterinary Pathology, Faculty of Veterinary Sciences and Animal Husbandry SKUAST (K), Shuhama, Alusteng, Jammu and Kashmir, India

²Veterinary Clinical Complex, Faculty of Veterinary Sciences and Animal Husbandry SKUAST (K), Shuhama, Alusteng, Jammu and Kashmir, India

NASHIRUDDULLAH, N., M. M. DARZI, S. A. KAMIL, M. S. MIR, F. PEER: Comparative efficacy of fine needle aspiration and incisional biopsies in the diagnosis of bovine actinomycosis. Vet. arhiv 74, 443-452, 2004.

ABSTRACT

This paper describes clinical and pathomorphological aspects in two spontaneous cases of bovine actinomycosis. Efficacy of Fine Needle Aspiration Biopsy (FNAB) and incisional biopsy results are compared. FNAB seems to be a simple and rapid method for presumptive diagnosis of the disease. However, incisional biopsy has an added advantage over the former as it provides information regarding the nature of the pathohistological changes, but diagnosis is recently made. Diagnosis was established on the basis of involvement of the mandible with indurated swelling, microscopic finding of sulphur granules and demonstration of Gram-positive interwoven filamentous organisms, along with coccoid forms in the aspirate and in the core of the granulomas. All attempts to culture the organism were unsuccessful. However, *Staphylococcus aureus* proved to be a concomitant aerobic microbe. Presence of eosinophils in the lesions and their increased numbers in the blood was an additional finding in the present study.

Key words: actinomycosis, sulphur granules, lumpy jaw, biopsy, pathological findings

Introduction

Actinomycosis is a specific disease characterized by a classical rarefying mandibular osteomyelitis commonly known as “lumpy jaw” in cattle, caused by a Gram-positive, branching filamentous organism - *Actinomyces bovis*. The

* Contact address:

Dr. Mohammed Maqbool Darzi, Division of Veterinary Pathology, Faculty of Veterinary Sciences and Animal Husbandry, Shere-Kashmir University of Agricultural Sciences and Technology, Shuhama, Alusteng, Srinagar - 190 006, Jammu and Kashmir, India, Phone: +91 194 2262211; Fax: +91 194 2262211; E-mail: nawabn1@rediffmail.com

organism is an obligatory parasite on the mucous membranes of the oropharynx and predisposition to osteitis seems invariably to occur through direct extension of the infection from the gums, presumably following injury or as a complication of periodontitis of other causes (JUBB et al., 1993). The basic lesion is represented by granulation tissue having small abscesses, sulphur granules and occasionally draining sinus tracts.

The diagnosis of actinomycosis is chiefly based upon the isolation and identification of the causative organism. The diagnosis is usually made late because of difficulties in culturing the organism (BURNS et al., 1997). Thin needle aspiration cytology is a well-known minimally invasive technique used in the diagnosis of neoplastic diseases. The same method has been employed for the identification of actinomycosis in humans (POLLOCK et al., 1978). The present paper presents two spontaneous cases of bovine actinomycosis whose diagnosis was established on the basis of microscopic study of the fine needle aspiration and incisional biopsies. The comparative efficacy of the two biopsies is elucidated.

Materials and methods

Two bovine clinical cases presented to the Veterinary Clinical Complex of the Faculty and later referred to Division of Veterinary Pathology, formed the materials of the present study.

A 5-year-old crossbred pregnant Jersey cow with a history of a 3-month-old proliferative overgrowth in the inter-mandibular space simulating neoplasia was presented. Another, four-year-old cow was presented with a firm granulomatous growth in the dorsal neck region behind the atlas. In the first case, Fine Needle Aspiration Biopsy (FNAB) was carried out from the depth of the growth and also from the mandibular lymph node with the help of an 18-gauge long needle. FNAB was also taken from the growth of the other cow. This was followed by incision biopsy of the growths in both cases. After making impression smears from the cut surface of the growths, the biopsy specimens were preserved in 10% buffered formalin for histopathological studies.

Smears from the fine needle aspirates, cut surfaces and pus materials were stained with Gram's stain, Lactophenol Cotton Blue, Giemsa, Methylene blue and Ziehl Neelsen's acid fast stain. Some unstained smears were prepared after crushing the granules observed in the exuded pus material between two slides and studied directly under a microscope.

Five-micron-thick sections of the biopsy specimens were prepared and stained with Harris' haematoxylin and eosin. Duplicate tissue sections were stained with MacCallum Goodpasture Gram stain, Brown and Brenn Gram stain, Kossa's Calcium stain, McManus Glycogen stain (PAS), Grocott's Methenamine Silver stain (GMS), Ziehl Neelsen and Kinyoun's Acid Fast Bacteria stain as per LUNA (1968).

Collection of microbial specimen was carried out from direct pus material from deep-seated sites of the growths and the pus material processed as per the method of GOODFELLOW (1999). Briefly, the pus material was suspended in sterile saline in a universal bottle, shaken and then left to stand, while the granules settled down. Particles were then collected with an inoculating loop and transferred on 5% sheep blood agar plates as per standard protocol.

Blood was collected in EDTA 2 mg/ml from the jugular vein for haematological examination.

Results

Clinically, case 1 revealed a hard, indurated, swollen right mandibular region involving the horizontal ramus. The inter-mandibular space towards the right side showed presence of granulomatous excrescence covered with a scaly crust which, on peeling, revealed a bleeding raw-red granulation surface (Fig. 1). The ipsilateral mandibular lymph node was swollen. No lesions could be detected from the internal side of the mouth. In case 2, the extent of the granulomatous growth was limited to the dorsal neck region behind the atlas. Following the incision for biopsy, thick syrupy pus studded with coarse yellow-white granules was observed in both cases.

FNAB from the growths revealed abundant polymorphonuclear lymphocytes and also enlarged, vacuolated macrophages (Fig. 2). Neutrophils were also demonstrated in the aspirate of the mandibular lymph node. Crushed sulphur granules resembled cauliflower particles. Gram-positive interwoven filamentous bacteria in bunches were demonstrated in the aspirated smears (Fig. 3). Coccoid forms, although few, were seen among the numerous filamentous bunches. A few organisms were noted in the lymph node aspirate of case 1. The organisms were non acid-fast and did not stain with Lactophenol cotton blue. However, the organisms were clearly discernible with Giemsa stain, but not with Methylene blue.

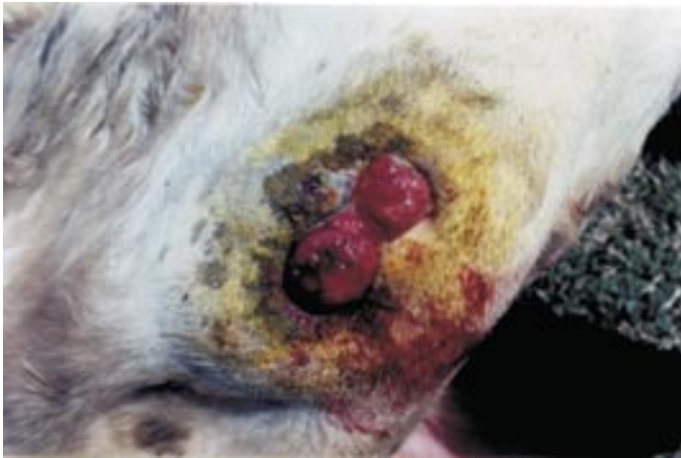

Fig. 1. Granulomatous excrescence in the intermandibular region of the cow affected with actinomycosis

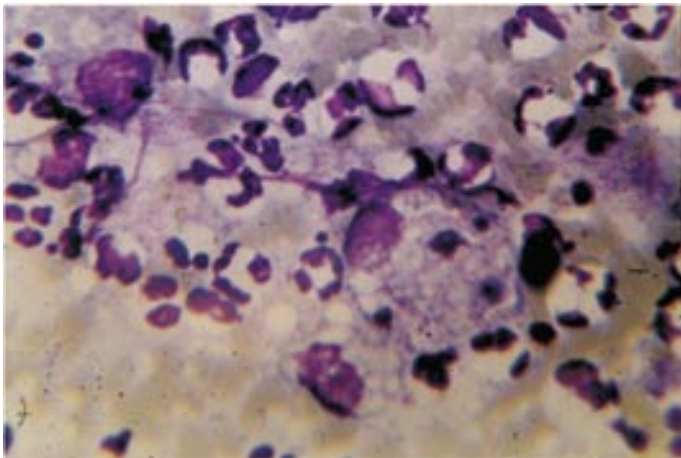


Fig. 2. Aspiration smear revealing numerous neutrophils and large vacuolated macrophages. Giemsa stain; $\times 100$.

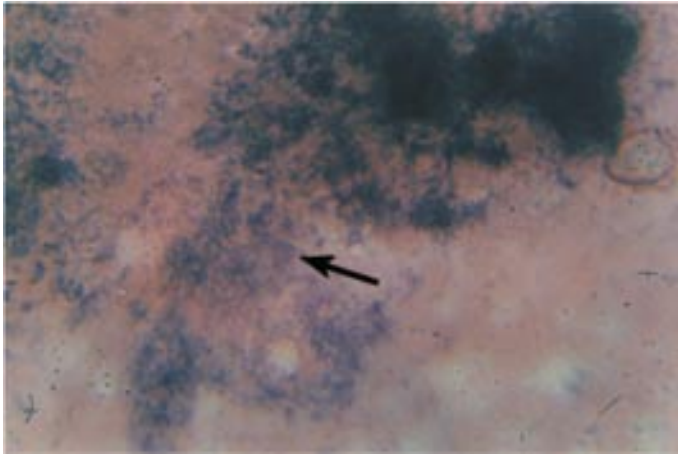


Fig. 3. Gram-positive interwoven filamentous organisms of *Actinomyces* sp. in aspiration smear. Coccoid forms are also noticed. Grams stain; $\times 100$.

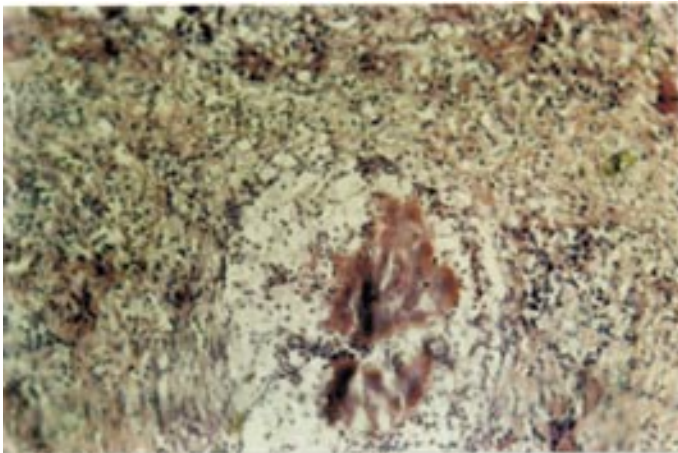


Fig. 4. Section of the incisional biopsy revealing granulomatous inflammation. The central eosinophilic core is surrounded by loosely arranged neutrophils and connective tissue. H&E; $\times 20$.

The typical club-shaped rosette formation was also clearly identifiable in unstained crushed smears of the sulphur granules. No organisms could be demonstrated in blood smears.

Histopathological study of the tissue biopsies revealed granulomatous inflammation containing small abscesses interspersed with fibrous tissue. The overlying skin in case 1 showed distinct parakeratosis.

With hematoxylin and eosin stain, the core of the granuloma comprised an eosinophilic irregularly shaped matrix (Fig. 4) which ranged in length from 150-650 μm and 100-350 μm in breadth. The central core of the mass showed numerous basophilic coccoid and filamentous organisms that were enclosed by eosinophilic fringes. The same core was found to be PAS positive and revealed granular calcium deposits with Kossa's calcium stain. The organisms were Gram positive when stained with MacCallum Goodpasture's and Brown and Brenn Gram stain but did not stain with PAS stain. However, the organisms were found to be non acid-fast when stained with Ziehl Neelsen's and Kinyoun's Acid Fast stains. With Grocott's Methenamine Silver stain the organisms stained black-brown. The long filamentous organisms were arranged along the periphery and were capped with eosinophilic clubs with lengths ranging from 7.5-18 μm . Immediately surrounding the central mass a loosely arranged neutrophilic reaction admixed with lymphocytic components was discernable. Other infiltrative cells composed of eosinophils were in close proximity to the clubs but were mostly distinguished diffusely in areas of fibroplasia. A fine connective matrix closely scaffolded the infiltrative cells. An outer boundary of a few macrophages was seen in some microgranulomas. No giant cells were visible.

The haematological picture in case 1 showed haemoglobin (Hb) count - 9 g/dl, Packed Cell Volume (PCV) - 42%, Total Leucocyte Count (TLC) - 12.050, Differential Leucocyte Count (DLC) - 76%, Lymphocytes (9.158), 15% Neutrophils (1.275), 2% Monocytes (241), 0% Basophils (0), and 7% Eosinophils (843).

Attempts to isolate *Actinomyces* sp. were unsuccessful. However, gram-positive *Staphylococcus aureus* could be isolated from the microbial specimens.

Discussion

Actinomyces sp. are obligatory parasites of the oropharynx in most animals and therefore lesions preferentially occur in adjacent tissues of the cervico-facial region. Breaching of mucosal integrity is an essential pre-requisite for establishment

of infection by the organisms. Requirements for tissue invasion are more complex than a single integumental defect. Presence of *Staphylococcus aureus* as an aerobic concomitant may build a negative redox potential or oxygen tension in the injured tissue and trigger an anaerobically favourable environment for the establishment of actinomycosis. Association of *Staphylococcus aureus* was described as most prevalent among the aerobic concomitants, but with the anaerobic components being more numerous and diverse (SCHAAL, 1998). Such concomitants have been associated in actinomycosis and often amplify the pathogenic potential of *Actinomyces* sp. by providing aggressive enzymes such as hyaluronidases and toxins (SCHAAL, 1998). The associated bacterial flora varies but is always present, unlike the other aerobic actinomycetes (*Nocardia*, *Actinomadura*, *Streptomyces*) that never contain a concomitant flora.

A presumptive diagnosis of *Actinomyces* sp. infection was based on the pathoanatomical changes, morphological and staining characteristics of the organisms in both smears and tissue sections so indifferent to its Gram-positive, non acid-fast and filamentous characters, although attempts at its isolation were unsuccessful. Brown and Brenn Grams stain, Grocott's Methenamine Silver stain, are specific for *Actinomyces* sp., as well as *Nocardia* sp. (LUNA, 1968), but the latter being acid fast readily differentiates between the two. Methylene Blue staining in smears could not stain the organisms, perhaps due to its reducing capacity (GOODFELLOW, 1999). However, as cautioned by SCHAAL (1998), the term "Actinomycoses" in the plural may be adopted to denote its often polyetiological inflammatory infection rather than a disease attributable to a single pathogen, thus being more linguistically and bacteriologically correct. Isolation of *Actinomyces* sp. is often difficult, especially where characteristic "sulphur granules" in pus or biopsy specimens are not detected, and it is often difficult to diagnose the condition (BURNS et al., 1997).

The clinical signs and histopathological observations conformed to the previously described pathology (JONES et al., 1996; JUBB et al., 1993). The immediate and obvious reason for a limited connective tissue reaction is possibly due to the early cell reaction as based on the relative recent history of the growths in both cases. Further, scanty macrophage and absence of any giant cell component further substantiates the relative immature form of the lesions. A massive accumulation of polymorphonuclear cells is reported to occur owing to a strong chemotaxis for these cells (GYLES, 1993). However, the presence of eosinophils in the lesions and their

increased numbers in blood is a significant finding associated with actinomycosis infection. Eosinophilic granuloma and blood eosinophilia in an atypical bovine allergic rhinitis case associated with *Nocardia* sp. has been reported in a pregnant cow (SHIBAHARA et al., 2001).

The sulphur granules are composed of bacterial filaments and mineralized calcium phosphate of host origin, the clubs representing encapsulation of the organisms by layers of a calcium phosphate-protein complex (PINE and OVERMAN, 1996). These clubs may vary in length from 1-15 μm , are reported to stain polyclonally for immunoglobulins (SWISHER, 2002) and may represent antigen-antibody complexes (GYLES, 1993). These eosinophilic clubs are termed as Spendore-Hoepli proteins, the phenomenon being associated with various other infections such as Actinobacillosis, Nocardiosis, certain fungal infections (JONES et al., 1996) and even with metazoan parasitic infestations. These proteins have been attributed to consist in part of eosinophil granule major basic protein in ascarid infection of man (HAMANN et al., 1989) and filarid infection in mice (MARTIN et al., 2000). The role of eosinophils in the present context may be of a similar nature and need to be further elucidated in view of its presence in the lesions and increased numbers in blood.

Although regional lymph nodes are reported to become large and indurated, they are reported not to be infected (JUBB et al., 1993). Enlargement of the mandibular lymph node, coupled with demonstration of poly-morphonuclear leukocytes and the causative organisms, are suggestive of lymphadenitis and is a significant finding.

FNAB is a minimally invasive technique. The histological feature of the sulphur granule remains intact allowing demonstration of the organisms in the aspirate. The technique seems to be safe and simple, allowing access to the extent of infection before specific treatment procedures can be adopted. The efficacy of aspiration specimens for the diagnosis of actinomycosis has been proven for morphological studies as well as microbiological isolations (POLLOCK et al., 1978). On the other hand, incisional biopsy assists in revealing the histopathological architecture and approximate chronicity of the lesions. However, the method provides late diagnosis as compared to FNAB.

References

- BURNS, B. V., A. AL-AYOUBI, J. RAY, J. B. SCHOFIELD, J. C. SHOTTON (1997): Actinomycosis of the posterior triangle: a case report and review of literature. *J. Laryngol. Otol.* 111, 1082-1085.
- GOODFELLOW, M. (1999): Actinomycetes: Actinomyces, Actinomadura, Nocardia, Streptomyces and related genera. In: Mackie and McCartney Practical Medical Microbiology (College, J. G., A. G. Fraser, B. P. Marmion, A. Simmons, Eds.) 14th ed. Churchill Livingstone. pp. 343-346.
- GYLES, C. L. (1993): Nocardia; Actinomyces; Dermatophilus. In: Pathogenesis of Bacterial Infections in Animals. (Gyles, C. L., C. O. Thoen, Eds.), 2nd ed. International Book Distributing Co., Lucknow, India. pp. 126-128.
- HAMANN, K. J., G. M. KEPHART, K. R. KAZACOS, G. J. GLEICH (1989): Immunofluorescent localization of eosinophil granule major basic protein in fatal human cases of *Baylisascaris procyonis* infection. *Am. J. Trop. Med. Hyg.* 40, 291-297.
- JONES, T. C., R. D. HUNT, N. W. KING (1996): Veterinary Pathology, 6th ed., Lippincott Williams & Wilkins, Philadelphia, Baltimore, New York, London, Buenos Aires, Hong Kong, Sydney, Tokyo. pp. 482.
- JUBB, K. V. F., P. C. KENNEDY, N. PALMER (1993): Pathology of Domestic Animals, Vol. I, 4th ed., Academic Press, New York, London.
- LUNA, L. G. (1968): Manual of Histologic Staining Methods of the Armed Forces Institute of Pathology. 3rd ed., McGraw-Hill Book Company, New York, Toronto, London, Sydney.
- MARTIN, C., L. LE GOFF, M. UNGEHEUER, P. N. VUONG, O. BAIN (2000): Drastic reduction of a filarial infection in eosinophilic Interleukin-5 transgenic mice. *Infect. Immun.* 68, 3651-3656.
- PINE, L., J. R. OVERMANN (1996): Differentiation of capsules and hyphae clubs of bovine sulphur granules. *Sabouraudia* 5, 141-143.
- POLLOCK, P. G., F. P. KOONTZ, T. F. VINER, C. J. KRAUSE, D. S. MEYERS, J. F. Jr. VALINCENTI (1978): Cervicofacial actinomycoses - Rapid diagnosis by thin-needle aspiration. *Arch. Otolaryngol.* 104, 491-494.
- SCHAAL, K. P. (1998): Actinomycoses, Actinobacillosis and Related Diseases. In: Topley & Wilson's Microbiology and Microbial Infections. (Hausler, W. J. Jr., M. Sussman Eds.) Vol. III, 9th ed. Arnold, London.
- SHIBAHARA, T., Y. MITARAI, Y. ISHIKAWA, M. SATOK, K. KADOTA (2001): Bovine nasal eosinophilic granuloma with blood eosinophilia caused by *Nocardia* species. *Aust. Vet. J.* 79, 363-365.
- SWISHER, B. (2002): Microorganisms. In: Theory and Practice of Histological Techniques. (Bancroft, J. D., M. Gamble, Eds.), 5th ed., Churchill Livingstone, London. pp. 337.

Received: 30 July 2003

Accepted: 8 November 2004

NASHIRUDDULLAH, N., M. M. DARZI, S. A. KAMIL, M. S. MIR, F. PEER: Usporedno istraživanje učinkovitosti postupaka aspiracije injekcijskom iglom i incizijske biopsije u dijagnostici aktinomikoze goveda. Vet. arhiv 74, 443-452, 2004.

SAŽETAK

Opisani su klinički i patomorfološki nalazi pri pojavi aktinomikoze goveda. Uspoređeni su rezultati polučeni aspiracijskom iglom i brizgalicom te incizijskom biopsijom. Aspiracija iglom i brizgalicom je jednostavna i brza metoda za uzimanje materijala na aktinomikozu. Međutim, incizijska biopsija ima prednost nad aspiracijom jer omogućuje patohistološku pretragu i brzo dijagnosticiranje bolesti. Dijagnoza je bila postavljena na osnovi indurativne otekline mandibule, mikroskopskog nalaza sumpornih zrnaca i dokaza gram-pozitivnih nitastih mikroorganizama istodobno s kokoidnim oblicima u aspiratu granuloma. Bezuspješni su bili svi pokušaji izdvajanja uzročnika. Vrsta *Staphylococcus aureus* dokazana je kao pridružena aerobna bakterija. Nalaz eozinofila u promijenjenom tkivu te njihov povećani broj u krvi omogućio je dodatno potvrđivanje dijagnoze.

Cljučne riječi: aktinomikoza, sumporna zrnca, biopsija, patološki nalazi
