

Some pathological changes in the tusks of wild boars (*Sus scrofa* L.) from Croatia and Slovakia

Dean Konjević^{1*}, Uwe Kierdorf², Zdravko Janicki¹, Alen Slavica¹, Tomislav Keros³, and Jan Čurlík⁴

¹Chair for Game Biology, Pathology and Breeding, Faculty of Veterinary Medicine, University of Zagreb, Zagreb, Croatia

²Institute of General and Systematic Zoology, Justus-Liebig-University of Gießen, Germany

³Croatian Veterinary Institute, Zagreb, Croatia

⁴Department of Parasitology, Diseases of Fish, Bees and Game, University of Veterinary Medicine Košice, Košice, Slovakia

KONJEVIĆ, D., U. KIERDORF, Z. JANICKI, A. SLAVICA, T. KEROS, J. ČURLÍK:
Some pathological changes in the tusks of wild boars (*Sus scrofa* L.) from Croatia and Slovakia. Vet. arhiv 74, 383-393, 2004.

ABSTRACT

The wild boar (*Sus scrofa* L.) is an autochthonous game species in large parts of Europe, and the permanent canines (tusks) of males are traditionally taken as trophies. Even though the tusks of shot animals have been closely examined only a few cases of wild boar tusk pathology have been described. In this paper, four different types of tusk pathology are presented. Eight samples were collected in Croatian hunting grounds during regular hunting operations, while one pair of canines originated from Slovakia. The tusk pathology described as type 1 is attributed to inflammation and partial necrosis of the dental pulp, caused by bacterial invasion. It is further assumed that infection of the enamel organ then caused the extended enamel hypoplasias, which characterize the shape of the teeth. The other three types of tusk pathology are diagnosed as being the result of either incomplete or complete extra- or intra-alveolar tusk fracture.

Key words: wild boar, tusk pathology, enamel hypoplasia, fracture, Croatia, Slovakia

Introduction

The wild boar (*Sus scrofa* L.) is an autochthonous game species of Croatia (ANDRAŠIĆ, 1979) and other European countries. The permanent dentition of the

* Contact address:

Dean Konjević, DVM, Chair for Game Biology, Pathology and Breeding, Faculty of Veterinary Medicine, University of Zagreb, Heinzelova 55, 10000 Zagreb, Croatia, Phone: +385 1 2390 156; Fax: 385 1 2441 390; E-mail: dean.konjevic@vef.hr

omnivorous wild boar comprises 44 teeth (THENIUS, 1989), the dental formula being I3/3, C1/1, P4/4, M3/3 (WAGENKNECHT, 1979; HERRE, 1986; THENIUS, 1989). A characteristic of the wild boar dentition is the presence of large, rootless and continuously growing permanent canines (tusks) in males. Compared with rooted teeth, continuously growing teeth are able to repair more actively and effectively due to their rich blood supply and the constant availability of formative tissues at their base (MILES and GRIGSON, 1990).

The normal growth of wild boar tusks compensates for the loss of enamel and dentine caused by constant wear between upper and lower canines. When the upper canine is absent the lower canine can reach an enormous length. Wild boar tusks are powerful weapons used against other males in aggressive encounters in the mating season. Boars also use their tusks to mark trees during that period. The risk of tusk injuries is therefore highest during that time of the year. Wild boar tusks are collected as trophies (FRKOVIĆ, 1989) and are therefore closely examined by hunters. Despite this, only a small number of cases of tusk abnormalities in wild boar have been reported in the scientific literature (PÁLAŠTHY and PÁLAŠTHY, 1989, 1990, 1991, 1992; KIERDORF and RÜHE, 2002; KIERDORF and KIERDORF, 2003). Knowledge of the variation in dentition and dental pathology is an important component of zoological and medical research. In this paper we present four different types of abnormality of permanent canines in male wild boars from Croatian and Slovakian hunting grounds, and discuss the possible pathogenesis of the malformations.

Materials and methods

All samples were opportunistically collected during regular hunting operations in the years 1999-2001 from free-living wild boars. Eight out of nine samples were collected in Croatian hunting grounds and one in Slovakia, thanks to the generosity of local hunters. All canines were already extracted from the jaws according to instructions for trophy preparation (FRKOVIĆ, 1989). Age estimation in the boars was performed based on the length of the whetting (occlusal) surfaces of the lower tusks and by applying the methods of Bieger and Brandt (WAGENKNECHT, 1979; FRKOVIĆ, 1989). The average value obtained by these methods was taken as the age at death of the respective individual. All samples were examined macroscopically and compared with previously reported pathology on the tusks of wild boars, elephants and hippopotamuses.

Results and discussion

Type 1. Six sets of tusks were obtained from wild boars shot during regular hunting operations in the area of Petrinja (Croatia, n = 5) and the area of Remeniny, near Vranov (Slovakia, n = 1). Age of the boars was estimated at 4-5 years. A major characteristic of most of these tusks is a distinct ledge that separates a coronal portion with normal circumference from an apical tooth portion with reduced circumference, as is illustrated in Fig. 1. In four of the six samples a ledge was present in both upper and lower tusks, whereas in the other two only the lower tusks exhibited this anomaly. In one sample the anomaly was placed unilaterally, only on the right side of the jaw. The ledges were mostly of a symmetrical nature in a tusk pair. The positions of the ledge along the long axis of the tusks varied among the individuals, as did the distinctness of the ledge, being dependent on 1) the time during odontogenesis when the insult to the secretory ameloblasts had occurred, and 2) the age of the respective wild boar and thus the wear state of its tusks. With ongoing attrition, a ledge present in a tooth will attain an increasingly incisal position. Along with this “distal shift” of the ledge, the risk of fracturing of the respective canine is likely to increase (as seen in three samples), since the hypoplastic area is very probably a zone of reduced resistance to mechanical forces. Contrary to the situation in the lower tusks, the ledges present in the upper tusks did not completely encircle the tooth (Fig. 1), which is explained by the fact that contrary to the lower canines, the enamel covering of upper tusks is typically confined to the anterior and lateral aspects of the tooth (THENIUS, 1989). In the affected lower canines the whetting surfaces exhibited a cleft-like opening leading into the pulp cavity. In contrast, the whetting surfaces of the upper canines were closed, even though some of them exhibited the changes in their apical portion (Fig. 2). Post-mortal splitting of the left lower tusk in one specimen had exposed a plug of reparative dentine that completely separated apical from coronal portion of the pulp cavity (Fig. 3). In one specimen the basal tooth portion exhibited signs of resorption, which indicates an inflammation of the periodontal tissue (Fig. 4). Macroscopic inspection of these tusks revealed an extended enamel hypoplasia, i.e. a quantitative defect in the enamel covering. Such hypoplastic lesions point to a disturbance of the process of enamel matrix formation by secretory ameloblasts (SCHROEDER, 1991). PÁLAŠTHY and PÁLAŠTHY (1991) and KIERDORF and KIERDORF (2003) have previously reported enamel hypoplasias in wild boar tusks, corresponding to the cases described here. Enamel




Fig. 1. Altered tusks of wild boar. Note the distinct ledge in apical portion of the mandibular and maxillary canines.



Fig. 2. The upper canines of wild boar with a distinct ledge in apical portion. Note the closed whetting surface (A).

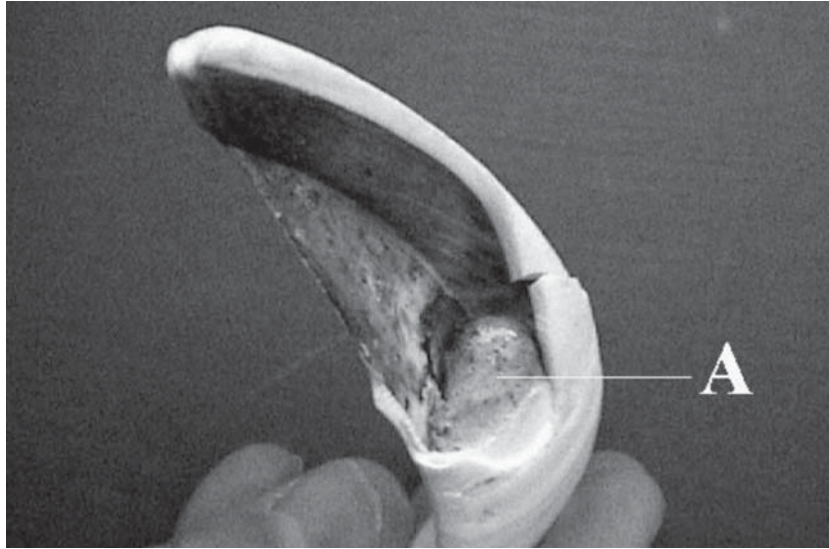


Fig. 3. A plug of reparative dentin (A) separating apical from incisal portion of a wild boar tusk

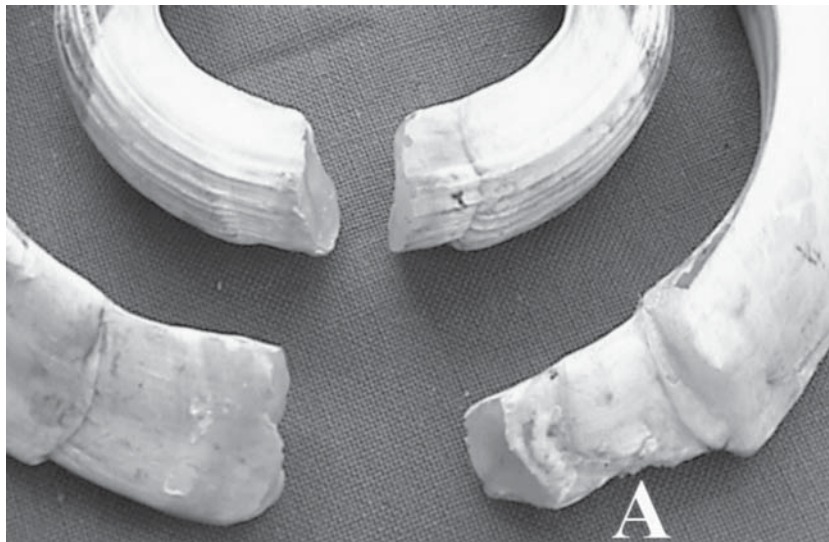


Fig. 4. Signs of inflammatory resorption (A) on the basal portion of the lower canine of wild boar

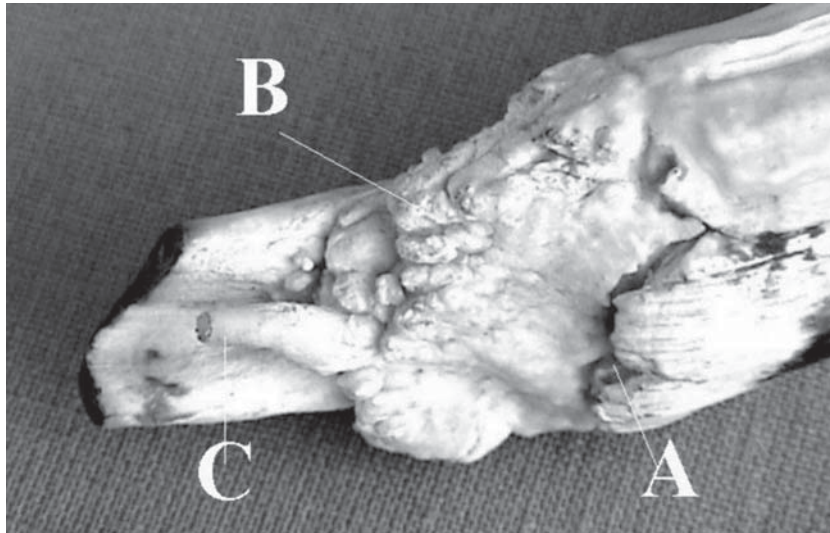


Fig. 5. The apical portion of the left upper canine. A: marked disruption in the enamel cover; B: irregularly shaped mass of reparative tissue; C: rod-shaped continuation of the dentine with circular opening.

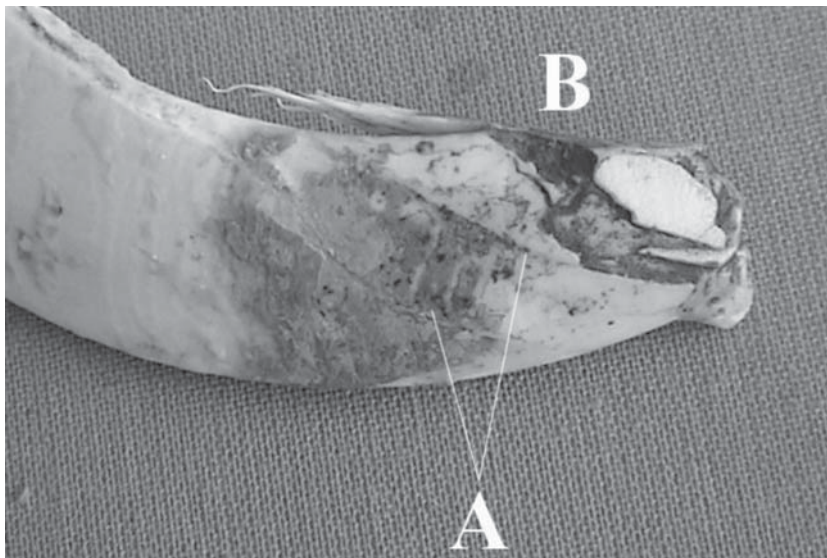


Fig. 6. Incomplete extra-alveolar fracture of left lower canine of a wild boar. Note the fracture lines in the enamel cover (A) and loss of occlusal surface (B).

hypoplasias are regarded as sequelae of the pathological changes of the dental pulp, denoting infection also of the enamel organ of the tusks, which, contrary to the situation in rooted teeth, remains active throughout life. Exposure of the pulp of wild boar tusks through openings in the dentinal wear surface has previously been described by PÁLAŠTHY and PÁLAŠTHY (1989; 1990; 1991; 1992) and KIERDORF and KIERDORF (2003). These authors assumed that this condition was most likely caused by insufficient formation of secondary dentine underneath the whetting surface of the tusks. Deposition of both secondary and tertiary dentine occurs as a response of odontoblasts to the dentinal irritation caused by attrition (MURRAY et al., 2003). If for any reason the production of these types of dentine ceases or the rate at which they are laid down does not keep pace with the removal of the dentine at the whetting surface, the pulp cavity will be opened.

Pulp exposure causes bacterial invasion and subsequent inflammation of the pulp, and can lead to partial or complete pulp necrosis (PRAPANPOCH et al., 1992; HARRAN-PONCE et al., 2002; LOVE and JENKINSON, 2002). Exposure and inflammation of the pulp, however, also induces a tissue response aimed at a recovery of the pulp. In teeth of continuous growth, like the tusks of elephants and hippopotamuses, the ability of the pulp for such repair processes is particularly pronounced, as is evidenced by the impressive cases of tusk repair following fracture and purulent inflammation compiled by MILES and GRIGSON (1990). A crucial step in this repair process is the deposition of reparative dentine, which is sometimes produced in very large amounts.

Formation of a plug of reparative dentine separating an incisal from an apical portion of the pulp cavity, which was observed in one left lower tusk (Fig. 3) and two upper tusks, matches observations on the lower tusks of a wild boar in Germany (KIERDORF and KIERDORF, 2003). This feature is interpreted as an attempt to demarcate the vital apical pulp moiety from the incisal, necrotic one. According to the above view, pulp inflammation and partial necrosis occurred as a consequence of insufficient dentine apposition underneath the whetting surface and subsequent opening of the pulp cavities of the wild boar tusks.

A further possible route of infection is indicated by LOVE and JENKINSON (2002), who described pulpitis and pulp necrosis as a consequence of bacterial invasion of dentinal tubules and diffusion of bacterial products through these tubules into the pulp. If unchecked, the infection can spread into the periodontal tissue. A prerequisite for this route of infection to occur is that at least some of the dentinal

tubules remain patent and are not obliterated as a reaction to dentinal irritation (SCHROEDER, 1991). If pulpal infection had occurred in either of these two ways, pulp necrosis would have prevented further dentine apposition underneath the whetting surface of the tusk. This would, in consequence, have led to an opening of the pulp cavity with ongoing attrition.

The symmetrical nature of these pathological changes excludes mechanical trauma as a causative agent.

Type 2. During the 2001 hunting season a boar with mass of 240 kg was shot in the area of Petrinja (Croatia). The individual's age was estimated at 7-8 years. The left upper canine exhibited a defect in its apical portion, while the other canines appeared normal. The pathological alterations of the left upper canine (Fig. 5) comprised a marked notch in the enamel cover as a consequence of an incomplete fracture (infraction), the presence of an irregularly shaped mass of reparative tissue (probably reparative dentine), and of a rod-shaped continuation of the dentine with a circular opening. The fracture line was most pronounced laterally and became less marked in a medial direction. This suggests that the traumatic impact on the tooth was exercised from lateral. The infraction affected the portion of the tusk located within the alveolus. Following the terminology of PÁLAŠTHY and PÁLAŠTHY (1991) we can therefore speak of a case of incomplete intra-alveolar fracture. It may be assumed that the infraction affected both enamel and dentine and went along with some dislocation of the fracture ends and exposure of the pulp cavity. The absence of enamel apically to the fracture line suggests partial destruction and dysfunction of the enamel (dental) organ as a consequence of the infraction and its sequelae (infection, inflammation and resorption). In places, traces of external resorption were present on the surface of the apical tooth portion, paralleling findings in cases of trauma to the periodontium of rooted teeth (ANDREASEN, 2003; BHAT et al., 2003).

Formation of the reparative dentine would constitute a case of hypertrophic tissue response caused by the severe irritation (and inflammation) of the dental pulp. The reparative tissue was most pronounced on the anterior and lateral aspects of the canine, suggesting that these were the areas of most intense damage to the dental pulp and consequent disturbance of pulp organization. This would accord with the view that the impact on the tooth came from lateral.

A major feature of the tusk was the presence of two separate growing ends, each with its own pulp cavity. The larger, medially located growing end was laterally

compressed and exhibited a longitudinal furrow. The smaller one ("C" in Fig. 5), which emanated from the mass of reparative tissue, possessed a circular opening. The presence of two growing ends suggests that in the course of re-establishment of pulp integrity a longitudinal splitting of the proximal tusk portion had occurred. As a consequence of this splitting, an additional small tusk ("C") began to form. The pathological changes reported for the wild boar tusk resemble quite closely those described for incompletely fractured elephant tusks by MILES and GRIGSON (1990), where the formation of additional small tusks has also been observed.

Type 3. A male boar with mass of 160 kg and aged 5 years was shot in the winter of 1999 in the area of Glina (Croatia). This individual exhibited an extra-alveolar infraction of the lower left canine and a complete loss of the occlusal surface of the upper and lower left canines (Fig. 6). The location of a fracture line in the enamel cover of the incisal part of the tooth (on the front side) suggests that the traumatic impact came from anterior. The impact was not severe enough to cause a complete fracture but led to an abnormal growth of the tooth. In principle, fractures of the coronal parts of the teeth can be classified into 1) fractures involving the enamel only, 2) fractures involving enamel and dentine, and 3) complicated fractures involving enamel, dentine and pulp (PINDBORG, 1970). If the traumatic impact was not of sufficient intensity to cause major displacement of the fragments, these can be re-united by dentine. A prerequisite for such reparative processes is that the dental pulp has survived the impact. A repair of the enamel lesions is, however, not possible. POPOWICS et al. (2001) noted that tooth fracture usually leads to changes in occlusal morphology of the teeth. In line with this statement, we observed the lack of a whetting surface on both the upper and the lower left canine due to the changes in tooth position.

Conclusion

The types of wild boar tusk pathology described here illustrate the remarkable potential of the tusk pulp to initiate and maintain repair processes. Our findings are parallel with observations on tusks of other species, e.g. in elephants and hippopotamuses, which also exhibit a high repair potential. The complete absence of upper canines reflects negatively on animal condition because the growth potential of the lower tusks can cause injuries of the upper jaw and interrupt the normal feeding process.

The most frequent influence of wild boar canines' pathology is manifested on their trophy values, as they are usually described as atypical and therefore cannot be evaluated. In other cases abnormal tusks exhibit smaller trophy value due to their temporary growth interruption. Further studies are encouraged to document the full spectrum of pathological changes in wild boar tusks and to establish the frequencies of different types of tusk pathology, in order to assess the influence of such pathology on individuals and on the whole population. Fig. 6. Incomplete extra-alveolar fracture of left lower canine of a wild boar. Note the fracture lines in the enamel cover (A) and loss of occlusal surface (B).

References

- ANDRAŠIĆ, D. (1979): Zoologija divljači i lovna tehnologija. SNL, Zagreb, Hrvatska.
- ANDREASEN, F. M. (2003): Transient root resorption after dental trauma: the clinicians dilemma. J. Esthet. Restor. Dent. 15, 80-92.
- BHAT, S. S., S. S. SHARAN, I. MADAN (2003): Healing of root resorption: a case report. J. Clin. Pediatr. Dent. 27, 235-238.
- FRKOVIĆ, A. (1989): Lovačke trofeje: obrada, ocjenjivanje i vrednovanje, Evropska divljač. Lovački Savez Hrvatske, Zagreb, Hrvatska.
- HARRAN-PONCE, E., R. HOLLAND, A. BARREIRO-LOIS, A. M. LOPEZ-BECEIRO, J. L. PEREIRA-ESPINEL (2002): Consequences of crown fractures with pulpal exposure: histopathological evaluation in dogs. Dent. Traumatol. 18, 196-205.
- HERRE, W. (1986): *Sus scrofa* Linnaeus, 1758 – Wildschwein. In: Handbuch der Säugetiere Europas, Band 2/II Paarhufer – Artiodactyla. (Niethammer, J., F. Krapp, Eds.). Aula, Wiesbaden, Deutschland, pp. 36-66.
- KIERDORF, H., U. KIERDORF (2003): Abnormal lower tusks in a male wild boar (*Sus scrofa* L.). Z. Jagdwiss. 49, 150-155.
- KIERDORF, H., F. RÜHE (2002): Tetrazyklinmarken an den permanenten Eckzähnen von Wildschwein-Keilern (*Sus scrofa* L.). Z. Jagdwiss. 48, 114-118.
- LOVE, R. M., J. F. JENKINSON (2002): Invasion of dentinal tubules by oral bacteria. Crit. Rev. Oral. Biol. Med. 13, 171-183.
- MILES, A. E. W., C. GRIGSON (1990): Colyer's Variations and Diseases of the Teeth of Animals, Revised ed. Cambridge University Press, Cambridge, UK, pp. 404-419.
- MURRAY, P. E., I. ABOUT, P. J. LUMLEY, J. C. FRANQUIN, L. J. WINDSOR, A. J. SMITH (2003): Odontoblast morphology and dental repair. J. Dent. 31, 75-82.
- PÁLAŠŤHY, J., S. PÁLAŠŤHY (1989): Regenerácia diviacieho kla (dentes canini) u svine divej (*Sus scrofa*) po trieštivej fraktúre. Zborník Vyhodoslov. Múzea. Prírod. Vedy 30, 99-102.

D. Konjević et al.: Some pathological changes in the tusks of wild boars (*Sus scrofa* L.) from Croatia and Slovakia

- PÁLAŠŤHY, J., S. PÁLAŠŤHY (1990): Osobitá anomália diviačích klov. Folia Venatoria 20, 267-277.
- PÁLAŠŤHY, J., S. PÁLAŠŤHY (1991): Klassifikation von Eckzahnanomalien beim Wildschwein. Z. Jagdwiss. 37, 195-203.
- PÁLAŠŤHY, J., S. PÁLAŠŤHY (1992): Ďalšie poznámky k vyskytu anomálnych diviačích klov na niektorých lokalitách Slovenska v rokoch 1987-1988. Folia Venatoria 22, 75-89.
- PINDBORG, J. J. (1970): Pathology of the Dental Hard Tissues. Munksgaard, Copenhagen, Denmark, pp. 278-280.
- POPOWICS, T. E., J. M. RENSBERGER, S. W. HERRING (2001): The fracture behaviour of human and pig molar cusps. Arch. Oral Biol. 46, 1-12.
- PRAPANPOCH, A., B. DOVE, J. A. COTTONE (1992): Morphometric analysis of the dental pulp chambers: a method of age determination in humans. Am. J. Forens. Med. Pathol. 13, 50-52.
- SCHROEDER, H. E. (1991): Pathobiologie oraler Strukturen, 2. Auflage. Karger, Basel, Switzerland.
- THENIUS, E. (1989): Zähne und Gebiß der Säugetiere. Handbuch der Zoologie, Band 8, Teilband 56. De Gruyter, Berlin, Deutschland.
- WAGENKNECHT, E. (1979): Altersbestimmung des erlegten Wildes. 5. Aufl. J Neumann-Neudamm, Melsungen, Deutschland, pp. 86-96.

Received: 5 December 2003

Accepted: 3 September 2004

KONJEVIĆ, D., U. KIERDORF, Z. JANICKI, A. SLAVICA, T. KEROS, J. ČURLÍK:
Neka patološka stanja na kljovama veprova (*Sus scrofa* L.) iz Hrvatske i Slovačke.
Vet. arhiv 74, 383-393, 2004.

SAŽETAK

Divlja svinja (*Sus scrofa* L.) je autohtona divljač većeg dijela Europe, čiji se trajni očnjaci (kljove) tradicionalno uzimaju kao trofeji. Usprkos činjenici da su kljove kao trofeji odstrijeljenih životinja temeljito pregledane nakon svakog lova, svega je nekoliko opisanih patoloških stanja na veprovim kljovama. U radu su predstavljena četiri različita tipa patološki promijenjenih kljova. Osam uzoraka prikupljeno je u lovištima na području Republike Hrvatske, a jedan u Slovačkoj, tijekom redovnih odstrjela. Patološko stanje opisano kao tip 1 pripisano je upalnim procesima i djelomičnoj nekrozi zubne pulpe, uzrokovanoj bakterijskom infekcijom. Oštećenje caklinskog organa uzrokovalo je hipoplaziju cakline i karakterističan izgled zuba. U preostala tri tipa opisane su razlike i moguće posljedice izvan i unutar alveolarnog nepotpunog i potpunog prijeloma očnjaka u divlje svinje.

Ključne riječi: divlja svinja, patologija kljova, hipoplazija cakline, prijelom, Hrvatska, Slovačka
