

**Ovarian adenocarcinoma in a guinea fowl (*Numida meleagris*)
- a case report**

**Raja Kumar, Madhavan Gopalakrishnan Nair, Avinash Warundeo
Lakkawar, and Khub Chandra Varshney***

*Department of Veterinary Pathology, Rajiv Gandhi College of Veterinary and Animal Sciences,
Kurumbapet, Pondicherry, India.*

KUMAR, R., M. G. NAIR, A. W. LAKKAWAR, K. C. VARSHNEY: Ovarian adenocarcinoma in a guinea fowl (*Numida meleagris*) - a case report. Vet. arhiv 74, 245-249, 2004.

ABSTRACT

An adult guinea fowl maintained in the poultry farm of the institute died suddenly without manifesting any premonitory clinical signs. On necropsy, highly vascular pedunculated multiple growths were seen on the ovary. The growth, which originated from the ovary, was histopathologically confirmed as adenocarcinoma with transcoelomic spread over the duodenal serosa. An incidence of ovarian adenocarcinoma in guinea fowls and its transcoelomic spread has not been reported earlier.

Key words: guinea fowl, ovarian tumour, adenocarcinoma, pathological findings

Introduction

Information on the incidence of naturally occurring neoplasms among avian species in general is meagre. Most studies of avian tumours have focussed attention on viral etiology, either due to their economic importance or as models for human cancers. Reports on non-viral tumours are also

* Contact address:

Dr. Khub Chandra Varshney, MVSc., Ph.D., Post Doc. (U.K), Professor & Head, Department of Veterinary Pathology Rajiv Gandhi College of Veterinary and Animal Sciences, Kurumbapet, Pondicherry - 605 009, India, Phone: +91 413 2273 001 extn. 215; Fax: +91 413 272 005; E-mail: ragacovas@vsnl.com

very limited in commercial chicken and turkeys due to their shorter life span than required for such tumours. An investigation of nodular lesions observed at slaughter in poultry indicated that 90% of the nodules were tumours and that 70% of them were adenocarcinomas, probably derived from the reproductive tract (REECE, 1997).

There are reports on long-term studies of flocks of aged chickens, ducks, and other species maintained in captivity, and also in wild birds (REECE, 1997). In spontaneous neoplasms described in specific pathogen-free (SPF) white leghorn chickens from United States of America, the prevalence of reproductive tract tumours was reported to be greater, and among these approximately 74% accounted for ovarian tumours (FREDRICKSON, 1987).

The present communication deals with a case of ovarian adenocarcinoma in a guinea fowl.

Materials and methods

An adult guinea fowl maintained at the institute was presented for post-mortem examination with a history of sudden death. A detailed post-mortem examination was conducted and the gross findings were recorded. Representative tissue samples from various organs were collected in 10% neutral buffered formalin and were processed. Sections were made at four micrometers thickness and stained by Haematoxylin and Eosin staining technique, and also periodic acid-Schiff (PAS) method (LUNA, 1972).

Results

On necropsy, the entire abdominal cavity was filled with highly vascular, pedunculated, greyish-white fleshy growths. Interestingly, ascites was absent. The mass, which weighed 300 g was found attached to the ovary (Fig. 1). The walls of the duodenum were thickened and had variably sized nodules of 2-5 mm diameter on the serosal surface (Fig. 2) resulting in constriction of the lumen of the affected area. No gross abnormalities were seen in the oviduct, adrenal glands or the spleen. Hepatosis, with distension of the gall bladder, nephrosis, pulmonary congestion and oedema were the other morbid changes noticed.

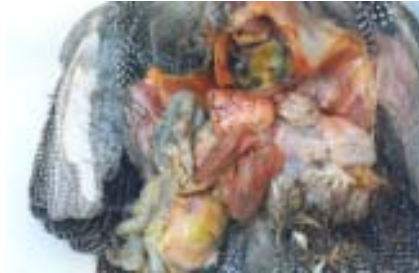

Fig. 1. Fleshy, vascular pedunculated growths on the ovary with nodular lesions on the duodenal serosa, congestion of lungs and hepatosis

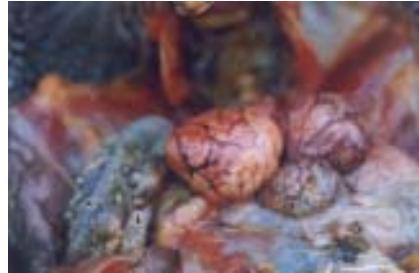

Fig. 2. Close-up of the vascular ovarian growth with metastatic nodules (arrowhead) on the serosa of the duodenum

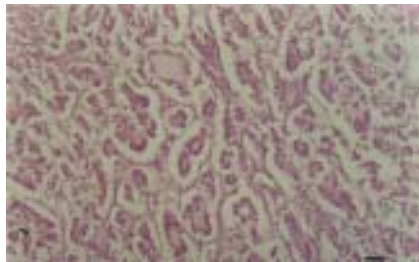

Fig. 3. Ovary - showing tubulo-acinar arrangement of the neoplastic cells with scanty stroma. H&E; $\times 400$; scale bar = 17.5 μm .

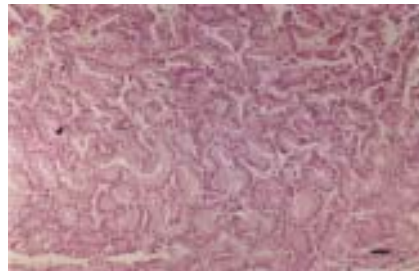


Fig. 4. Duodenum - metastatic nodule in the serosa showing tubulo-acinar arrangement of the neoplastic cells. H&E; $\times 400$; scale bar = 17.5 μm .

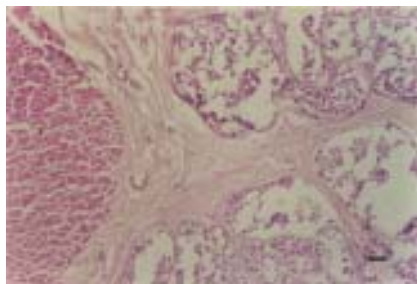


Fig. 5. Duodenum - fibrous tissue encapsulation and lobular arrangement of the metastatic nodule in the serosa. H&E; $\times 100$; scale bar = 70 μm .

Microscopically, the ovarian growth consisted of a tubulo-acinar arrangement of a single layer of low columnar eosinophilic epithelial cells with basal, round nuclei (Fig. 3). In focal areas, a papillary type of arrangement of the cells was noticed. Stromal tissue was scanty. A few acini contained PAS-positive material. Mitotic figures were also very few. The intestinal nodules were composed of a tubulo-acinar arrangement of low columnar epithelial cells on the serosal layer (Fig. 4) and were similar to those observed in the ovarian tissue. Intestinal growths contained a moderate amount of fibrous tissue encapsulating as well as dividing the mass into lobules (Fig. 5). The oviduct mucosa showed epithelial denudation and there was no evidence of neoplasia.

Liver showed moderate fatty changes with periportal infiltration of mononuclear cells. The renal tubules showed a moderate degree of coagulative necrosis and focal infiltration of mononuclear cells in the interstitium. There was a severe degree of pulmonary congestion, with a mild degree of oedematous changes. Metastatic foci could be observed only in the duodenum, but not in liver, kidneys, adrenals, lungs, spleen or heart.

Discussion

The incidence of ovarian adenocarcinomas in domestic fowls has been reported earlier (REECE, 1996; REECE, 1997). Although the cell of origin of ovarian adenocarcinoma in poultry is unknown, it is presumed to arise from the germinal epithelium (REECE, 1997). Also, FREDRICKSON (1987) has postulated that they may be derived from thecal glands, interstitial cells, remnants of embryonic sex cords or the mesonephros. According to REECE (1997), metastatic abdominal adenocarcinomas may originate from either the ovary or the oviduct, and their differentiation can be difficult, since in both cases the ovary and oviduct are simultaneously involved. However, in the present case, failure to detect tumour growth in the mucosal lining of the oviduct indicates that the tumour is not of oviductal origin. Based on the histological appearance of the growth in the ovary and absence of any growth in the oviduct, the tumour was diagnosed as ovarian adenocarcinoma with metastasis on the duodenum. The gross and

R. Kumar et al.: Ovarian adenocarcinoma in a guinea fowl (*Numida meleagris*) - a case report

microscopic observations made in this case concurred with earlier reports in other avian species (REECE, 1997). However, the incidence of ovarian adenocarcinoma in guinea fowls and its transcoelomic spread has not been reported earlier.

Acknowledgements

The authors are grateful to the Dean, Rajiv Gandhi College of Veterinary and Animal Sciences, for providing the facilities and encouragement.

References

- FREDRICKSON, T. N. (1987): Ovarian tumours of the hen. *Environ. Health Perspect.* 73, 35-51.
- LUNA, L. G. (1972): *Histologic staining methods of the Armed Forces Institute of Pathology.* 3rd ed., McGraw Hill Book Co., New York, pp. 12-17, 32-37, 159.
- REECE, R. L. (1996): Some observation on naturally occurring neoplasms of domestic fowls in the state of Victoria, Australia (1977-87). *Avian Path.* 25, 407-447.
- REECE, R. L. (1997): Tumours of unknown etiology. In: *Diseases of Poultry* (Calnek, B. W., Ed.), 10th ed., Iowa State University Press, Ames, Iowa, pp. 459-463.

Received: 24 March 2003

Accepted: 4 May 2004

KUMAR, R., M. G. NAIR, A. W. LAKKAWAR, K. C. VARSHNEY: Adenokarcinom jajnika u biserke (*Numida meleagris*). *Vet. arhiv* 74, 245-249, 2004.

SAŽETAK

U radu je prikazan slučaj uginuća odrasle biserke bez prethodnih znakova bolesti. Pri razudbi su na jajniku utvrđene dobro vaskularizirane pedunkulirajuće multiple tvorbe. Patohistološki je ustanovljen adenokarcinom s transcelomnim širenjem preko seroze duodenuma. Ovo je prvi prikaz adenokarcinoma jajnika i njegova transcelomskog širenja u biserke.

Ključne riječi: biserka, tumor jajnika, adenokarcinom, patološki nalaz
