

## Sialography in dog: normal appearance

Mina Tadjalli<sup>1</sup>, Seifollah Nazhvani Dehghani<sup>2\*</sup>, and Mehrdad Basiri<sup>2</sup>

<sup>1</sup>*Department of Veterinary Anatomical Science, School of Veterinary Medicine, University of Shiraz, Shiraz, Iran*

<sup>2</sup>*Department of Veterinary Surgery, School of Veterinary Medicine, University of Shiraz, Shiraz, Iran*

---

**TADJALLI, M., S. N. DEHGHANI, M. BASIRI: Sialography in dog: normal appearance. Vet. arhiv 74, 225-233, 2004.**

### ABSTRACT

The anatomy of dog salivary glands was studied on cadaver heads. The mandibular duct enters the oral cavity on the sublingual caruncle. The parotid gland duct enters the oral cavity on the cheek opposite the 4<sup>th</sup> upper premolar tooth. The zygomatic salivary gland duct enters the oral cavity opposite the first upper molar tooth. Prior to applying sialography to live animals, catheterization, injection and radiography techniques had to be carried out on cadaver heads. Subsequently, these techniques were applied on five live dogs. The animals were routinely anaesthetized, the mandibular, parotid and zygomatic ducts catheterized, and contrast medium was injected into each gland. Lateral radiographs were made immediately after injection. The normal dog mandibular, parotid and zygomatic salivary glands as depicted on sialograms have a multilobular appearance in cadaver heads, but in live animals the outline of gland, main ducts and their smaller branches could be identified. The parotid duct leaves the deep surface of the rostral end of the gland and courses over the masseter muscle before it enters the mouth. The mean diameter of parotid duct was  $1.0 \pm 0.4$  mm. The mandibular duct leaves the rostral end of the gland, and its mean diameter was  $1.0 \pm 0.2$  mm. The zygomatic duct was also  $1.0 \pm 0.2$  mm in diameter. In conclusion, sialography of mandibular, parotid and zygomatic salivary gland in dog is practical and is helpful in the diagnosis of some pathological conditions in these glands.

**Key words:** dog, sialography, mandibular gland, parotid gland, zygomatic gland, salivary glands

---

\* Contact address:

Dr. Dehghani Seifollah Nazhvani, Department of Veterinary Surgery, School of Veterinary Medicine, University of Shiraz, Shiraz, 71345-1731, Iran, Phone: +98 711 6280 702; Fax: +98 711 6280 707; E-mail: sdehghan04@yahoo.com

## **Introduction**

Contrast radiography has been used in the diagnosis of salivary gland diseases in canines by HARVEY(1969). The technique of sialography and its normal radiographic appearance in live cattle have been described by DEGHANI et al. (1994), in live sheep by DEGHANI et al. (2000a), in live camel by DEGHANI et al. (2000b), and in live goat by TADJALLI et al. (2002). Differential diagnoses of salivary gland pathological conditions include foreign bodies occasionally found in the salivary duct, salivary calculi (sialoliths) causing obstruction. Inflammation and neoplasm of the salivary glands have been reported by JUBB et al. (1985). These conditions are rarely seen in all species but have been reported in cattle, sheep, pigs, horses, and cats. Sialoliths are reported in donkey by DEGHANI and TABATABEI (1993).

Therefore, the purpose of this study was to cannulate the duct of the mandibular, parotid and zygomatic salivary gland of a dog cadaver and, using retrograde injection of contrast medium, to arrive at a clinically useful sialography protocol. In a second phase, these techniques were applied to live healthy dogs to allow description of the radiographic appearance of normal mandibular, parotid and zygomatic salivary glands.

## **Materials and methods**

A  $21.0 \pm 1.5$  kg mass of cadaver heads of five adult dogs were used to study the anatomy of salivary glands, their ducts and duct entrance into the oral cavity. Subsequently, sialography of the salivary glands was accomplished. Additionally, sialography was performed on five live, clinically healthy adult dogs to assess the feasibility of the technique. The animals were handled according to University of Shiraz University regulations and policies for animal rights.

*Anatomic study.* The orifice through which the saliva of the glands enters the oral cavity was identified. The skin over each gland was incised, the fascia dissected, each gland carefully freed from surrounding tissue and the ducts isolated along the entire length until they reached the oral cavity. Salivary gland capsules were removed. The isolated glands were weighed and their length and width measured.

#### Sialography of the parotid gland

*Cadaver study.* The mouth was held open with a mouth gag and the parotid duct orifice was identified opposite the upper 4<sup>th</sup> premolar tooth on both sides of the oral cavity. In order to be able to catheterize the duct a special catheter was developed. A 20-gauge, 5 cm-long needle was used, its sharp end being reduced to make it atraumatic. The whole length of the needle could be introduced into the duct and 2 ml of iodinated (Telebrix38, 380 mg/ml, sodium and meglumine Ioxitalamate, Guerbert, France) water soluble contrast medium was injected. Lateral radiographs were subsequently made, with the cassette placed under the side being evaluated, and exposed from the opposite side of the head.

*Live animal study.* Five live dogs with masses of  $22.0 \pm 3$  kg were sedated with 0.5 mg/kg Acetylpromazine (KELA Laboratories NV-Belgium) intramuscularly and anesthetized by examine (5 mg/kg; Ketamin Hcl). A mouth gag was applied, an assistant grasped the tongue and it was pulled slightly towards the side that was not being evaluated. The orifice of the parotid duct was identified. Five cm of the needle was inserted into the parotid duct, followed by an injection of 2 ml of iodinated water-soluble contrast medium. Immediately following the injection, radiographs were made using the technique for cadaver head study.

#### Sialography of the mandibular gland

*Cadaver study.* Cadaver heads were positioned. The duct orifice of the mandibular salivary gland could be identified on the sublingual caruncle. An 18-gauge 5 cm rigid atraumatic needle was used to catheterize the mandibular duct. The entire length of the needle was inserted into the duct and 2 ml of contrast medium was injected. Radiographs were subsequently made using a similar technique.

*Live animal sialography.* The live dogs used for the previous study were also used for mandibular sialography. The sublingual caruncle and mandibular gland orifice was identified, the entire length of a previously prepared needle was inserted into the duct and 2 ml of contrast medium was injected.

Radiographs were subsequently made using techniques similar to those used for cadaver study.

### Sialography of zygomatic salivary gland

*Cadaver study.* The zygomatic gland is situated in the rostral part of pterygopalatine fossa which has four or five ducts which open near the last upper cheek tooth. The major duct is as large as the parotid duct. Minor ducts are small. The major duct was catheterized and radiographed similarly to the other glands.

*Live animal study.* The location of the major duct orifice was identified, catheterized and radiographed similarly to the other glands.

### Results

The parotid glands are irregularly triangular and are located ventrally to the wing of the atlas vertebrae which at its wide part is attached to the base of the ear. Its ventral end is narrow, covers the regional lymph node and is in contact with the mandibular gland ventrally. The parotid duct, formed from several small branches, leaves the gland at the ventral and rostral surface, crosses over the masseter muscle, and is located between the muscle and the facial vein and artery. It enters the oral cavity opposite the 3<sup>rd</sup> upper cheek tooth (3<sup>rd</sup> pre-molar). The mean of the wide part of the parotid gland was  $2.08 \pm 0.28$  cm, mean length was  $3.96 \pm 0.26$  cm and mean mass was  $6.93 \pm 0.14$  gm. In survey radiographs of the parotid gland

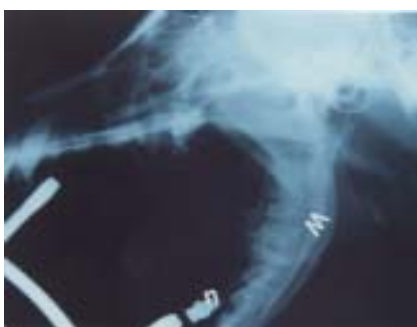

Fig. 1. Lateral plain radiograph of a dog cadaver head. None of the salivary glands are visible. Mandible (M), Wing of Atlas (A). A catheter (n) is located in the mandibular duct orifice.

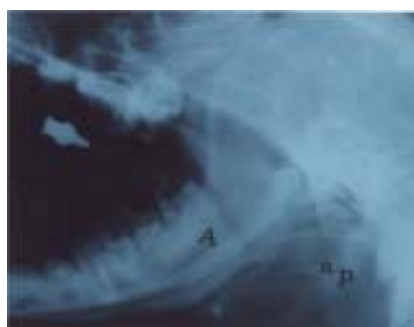


Fig. 2. Normal parotid (P) sialogram in a cadaver dog head. Major parotid duct (A). Smaller parotid duct branches (a).

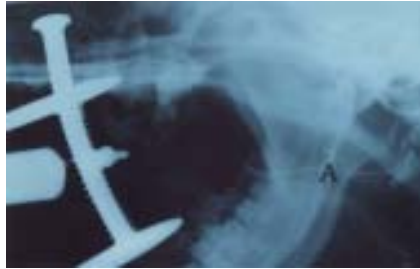

Fig. 3. Normal parotid sialogram of a live dog. Parotid duct (A) and parotid gland (P). Note the triangular shape of the parotid gland.

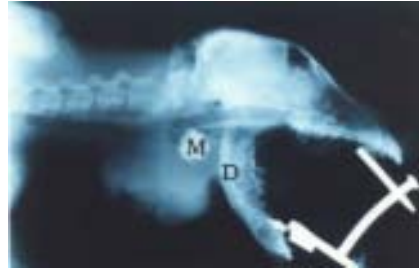


Fig. 4. Normal mandibular sialogram of a mature dog head. Mandibular duct (D). Mandibular gland (M). The dog was affected with a large mass under the neck. Sialogram was of assistance in visualizing the normal, unaffected, mandibular gland.

there was no demarcation of the gland (Fig.1) After injection of contrast medium, the gland was visible and appeared as a lobulated structure located ventrally to the wing of atlas (Fig. 2) The sialograms clearly depicted the parotid duct in the centre of the gland as well as associated smaller branches. Only the main duct could be identified outside the gland. Average diameter of the parotid duct was 1 mm. The mean width and length of parotid gland depicted on the sialograms was  $2.08 \pm 0.16$  cm and  $3.96 \pm 0.26$  cm in

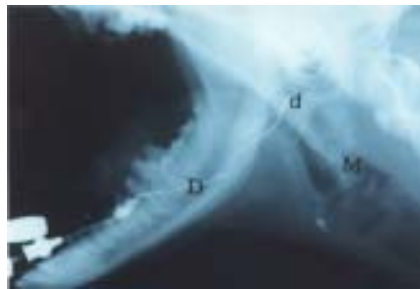


Fig. 5. Normal mandibular sialogram in a mature live dog. Mandibular duct (D). Smaller mandibular branches (d). Mandibular gland (M).

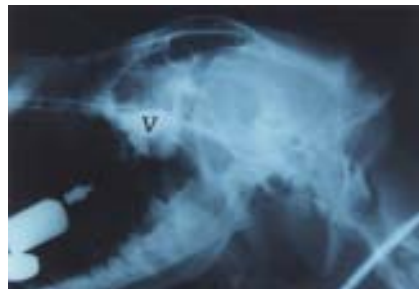

Fig. 6. Normal zygomatic sialogram in a mature live dog head. Zygomatic gland (V).

cadaver and  $2.0 \pm 0.12$  cm and  $4.0 \pm 0.3$  cm in live animals, respectively. The appearance of the parotid sialograms in live dogs was different from that in the cadaver study, and only the ducts and their smaller branches could be identified (Fig. 3) The mandibular duct leaves the gland on the medial surface, passes over the cranial part of digastricus and styloglossus muscles, opens into the mouth on the sublingual caruncle near the frenulum lingual. Several branches emerge from the main duct at the centre of the gland. The mandibular gland is in contact with the parotid gland both dorsally and medially (Fig. 4) The two mandibular glands are in close proximity rostrally. The mean mass, length and width of the gland are  $8.14 \pm 0.3$  gm,  $2.82 \pm 0.2$  cm and  $2.6 \pm 0.1$  cm, respectively. The mandibular gland was not visible in the survey radiographs (Fig. 1) On contrast radiographic studies, the mandibular gland could be clearly identified caudally to the mandibular angle (Fig. 2) The gland has a multilobulated appearance. The duct first runs dorsally and then rostrally to the sublingual caruncle. The mean diameters of the duct on cadaver and live animal sialogram were quite similar. The mean length and width of the gland depicted from cadaver sialograms, as well as in the live animal study, were  $3.2 \pm 0.5$  cm and  $2.25 \pm 0.24$  cm.

The appearance of the mandibular sialogram in live animals was dissimilar to that in the cadaver study. Only the ducts and their smaller branches could be identified (Fig. 5) The zygomatic gland is located in the rostral area of the pterygopalatine fossa and oro-ventral area of the orbital fossa and has four or five ducts that open near the last upper cheek tooth. The major duct is as large as the parotid duct. The mean length and width of this gland were  $2.8 \pm 0.35$  cm and  $2.6 \pm 0.2$  cm, respectively. Cadaver and live animal sialographic study revealed almost similar values for the length and width of this gland.

### **Discussion**

In this study the mandibular and parotid gland showed no significant differences in mass ( $8.14 \pm 0.3$  gm versus  $6.93 \pm 0.14$  gm). In cattle, it was reported that the mandibular gland was the largest salivary gland (DEGHANI et al., 1994). The mass of the mandibular and parotid gland was reported to be 9.0 gm and 11.0 gm, respectively, in sheep (GETTY, 1975). In

another study the mass of mandibular and parotid gland in sheep was reported to be  $16.2 \pm 4.6$  gm and  $13.5 \pm 2.6$  gm, respectively (DEHGHANI et al., 2000a). In goat the parotid and mandibular gland weighed  $15.2 \pm 3.2$  and  $14.7 \pm 3.8$  gm, respectively (TADJALLI et al., 2002). In camel the mass of parotid and mandibular gland was reported to be  $77.7 \pm 16.9$  gm and  $47.9 \pm 9.1$  gm, respectively (DEHGHANI et al., 2000b). Gland mass would depend to a certain extent on the mass of the animal. In this study the average mass of dogs was  $21.0 \pm 1.0$  kg. Only lateral radiographs were made because ventrodorsal or dorsoventral radiographs would contain an excessive amount of superimposition of the osseous structures from the skull and mandible. The parotid duct orifice could be identified opposite the 3<sup>rd</sup> upper cheek tooth. Catheterization of the parotid duct was possible in live animals after practicing on cadavers. By sedation and anesthetizing the animal, opening the mouth with a mouth gag and a light source, the duct can be easily catheterized. The mandibular duct orifice is represented by an opening on the border of an indistinct sublingual caruncle. The cadaver study facilitated its identification. The zygomatic gland is found only in carnivores among domestic animals. The sublingual gland is divided into two parts. The caudal is the monostomatic part, which is located on the occipitomandibular part of the digastricus muscle close to the mandibular gland. Its duct, the major sublingual duct, accompanies the mandibular duct and opens beside it or joins it, and was therefore very difficult to catheterize. BROWN (1989) and HARVEY (1969) used the sialography technique for diagnosis of glandular rupture, inflammation, distension, necrosis, fistula formation, and foreign bodies in the salivary gland of the dog and cat. WALDRON and SMITH (1991) reported A diagnosis of mucocel in dog. WANG et al. (1992) reported A diagnosis of chronic obstructive inflammation of the salivary gland in 23 cases. AKINE et al. (1991) diagnosed salivary cyst and tumour in 60%, and inflammatory conditions in 63% of cases by sialography. Sialolith (7x4 cm) was reported in the parotid duct of a donkey by DEHGHANI and TABATABEI (1993). The amount of contrast medium used to study gland parenchyma, as well as the main duct and possibly its branches in cadaver and live animals, was about 2 ml. For better quality sialograms in live dogs, increasing the amount of contrast medium to double the initial dose would be logical. The contrast radiographic technique and

normal glandular appearance described in this paper can assist in the diagnosis of many different salivary gland diseases in dog.

---

#### Acknowledgments

The authors wish to express their gratitude to Mr. Moslem Rezaei and Mr. Nasrollah Golchin for their technical assistance in making radiographs, and also to the University of Shiraz for its support.

#### References

- AKINE, I., N. ESMER, M. GERECEKER, S. AYTAC, I. ERDEN, H. AKAN (1991): Sialographic and ultrasonographic analysis of major salivary glands. *J. Article* 111, 600-606.
- BROWN, N. O. (1989): Salivary gland disease. Diagnosis, treatment and associated problems. *J. Article Review* 1, 281-294.
- DEHGHANI, S. N., C. J. LISCHER, U. ISELIN, B. KASER-HOTZ, J. A. AUER (1994): Sialography in cattle: technique and normal appearance. *Vet. Radiol. Ultra Sound* 35, 433-439.
- DEHGHANI, S. N., M. TADJALLI, M. H. MASUMZADEH (2000a): Sialography of Sheep parotid and mandibular salivary glands. *Res. Vet. Sci.* 68, 3-7.
- DEHGHANI, S. N., M. TADJALLI, S. T. MANUCHEHRY (2000b): Sialography in camel: technique and normal appearance. *J. Camel Practice Res.* 6, 295-299.
- DEHGHANI, S. N., A. TABATABEI (1993): Salivary calculi in donkey. *Ind. J. Vet. Surgery* 14, 94-95.
- GETTY, R. (1975): Sisson and Grossman's the anatomy of domestic animals. 5<sup>th</sup> ed. WB Saunders Co. Philadelphia, Vol. 1, 872-874.
- HARVEY, C. E. (1969): Sialography in the dog. *J. Am. Vet. Radiol. Soc.* 10, 18-27.
- JUBB, K. E., P. C. KENNEDY, N. PALMER (1985): Pathology of Domestic Animals. 3<sup>rd</sup> ed. Vol. 2. Newyork, Academic Press, pp. 22-23.
- TADJALLI, M., S. N. DEHGHANI, M. GHADIRI (2002): Sialography of the goat parotid, mandibular and sublingual salivary glands. *Small Ruminant Research* 44, 179-185.
- WALDRON, D. R., M. M. SMITH (1991): Salivary mucocels. *J. Article Review, Tutorial* 3, 270-276.
- WANG, S. L., Z. J. ZOU, Q. G. WU, K. H. SUN (1992): Sialographic changes related to clinical and pathologic findings in chronic obstructive parotitis. *J. Article* 21, 364-368.

Received: 9 June 2003

Accepted: 4 May 2004



---

**TADJALLI, M., S. N. DEGHANI, M. BASIRI: Sijalografija u psa: normalan prikaz. Vet. arhiv 74, 225-233, 2004.**

**SAŽETAK**

Anatomija žlijezda slinovnica psa istražena je na glavama lešina. Izvod mandibularne žlijezde ulazi u usnu šupljinu na podjezičnom karunkulu. Izvod zaušne slinovnice ulazi u usnu šupljinu na obraznoj stijenci nasuprot četvrtog gornjeg pretkutnjaka, a zigomatične slinovnice nasuprot prvog gornjeg kutnjaka. Prije nego što je provedena sijalografija na živim životinjama, učinjena je kateterizacija, ubrizgavanje i radiografija na glavama lešina pasa. Nakon anestezije životinjama je u izvodne kanale zaušne, mandibularne i zigomatične slinovnice stavljan kateter i ubrizgano kontrastno sredstvo. Laterolateralno radiografsko snimanje provedeno je odmah nakon ubrizgavanja. Na sijalogramima glava lešina mogla se utvrditi samo multilobularna građa za razliku od onih učinjenih na živim životinjama gdje su uočeni glavni izvodi i njihovi ogranci. Utvrđeno je da izvod zaušne žlijezde izlazi iz prednjeg kraja te prelazeći preko velikog žvačnog mišića ulazi u usnu šupljinu. Srednja vrijednost promjera izvoda zaušne žlijezde bila je  $1,0 \pm 0,4$  mm. Izvod mandibularne žlijezde izlazi iz prednjeg kraja žlijezde i promjera je  $1,0 \pm 0,2$  mm. Izvod zigomatične žlijezde bio je iste veličine. Zaključno je istaknuto da je sijalografija zaušne, mandibularne i zigomatične žlijezde metoda koja može biti od velike pomoći pri otkrivanju patoloških stanja tih žlijezda.

**Ključne riječi:** pas, sijalografija, mandibularna slinovnica, zaušna slinovnica, zigomatična slinovnica, žlijezde slinovnice

---