

## **A pathologic study on experimental *Erysipelothrix rhusiopathiae* cellulitis in broiler chickens**

**Amin Derakhshanfar<sup>1\*</sup>, Reza Ghanbarpour<sup>1</sup>, and Saleh Yazdani<sup>2</sup>**

<sup>1</sup>*Department of Pathobiology, Faculty of Veterinary Medicine, Shahid Bahonar University of Kerman, Kerman, Iran*

<sup>2</sup>*Veterinarian*

---

**DERAKHSHANFAR, A., R. GHANBARPOUR, S. YAZDANI: A pathologic study on experimental *Erysipelothrix rhusiopathiae* cellulitis in broiler chickens. Vet. arhiv 74, 217-224, 2004.**

### **ABSTRACT**

Avian cellulitis is a serious problem for the commercial broiler industry. Although various agents were isolated from cellulitis lesions, the ability of *Erysipelothrix rhusiopathiae* in reproduction of cellulitis is not known. Therefore, the objective of this study was to evaluate the ability of these bacteria for induction of avian cellulitis. The study involved two experimental groups, each consisting of twenty randomly selected 15-day-old, mixed sex, healthy, commercially grown broiler chickens of the same strain. A single scratch was induced with a 1.5-inch 18-gauge needle, creating a lesion 2 cm in length on the right dorsolateral surface of the body parallel to the vertebrae. In Group 1, 1ml of 10<sup>8</sup> bacterial suspension - isolated from a turkey cock with erysipelas - was inoculated into the scratches. Birds in Group 2 received 1ml of the sterile phosphate-buffered saline as negative controls. At 48-hr post inoculation the birds were killed and pathologic and bacteriologic examinations were carried out. Birds in Group1 showed weakness, depression and mild diarrhoea. In this group, 65% of birds showed swelling of the skin with necrosis, infiltration of heterophils and fibrinous exudates, which was characteristic of cellulitis. The remaining 35% of birds were dead within 24-hrs post inoculation, with signs of mild cellulitis. *Erysipelothrix rhusiopathiae* was recovered from skin and some other internal organs from birds in Group 1. Birds in Group 2 were normal. Results of the present study revealed that *E. rhusiopathiae* can be considered as a causative agent of avian cellulitis, with public health hazards.

**Key words:** *Erysipelothrix rhusiopathiae*, cellulitis, broiler chickens, erysipelas

---

\* Contact address:

Assistant Prof. Dr. Amin Derakhshanfar, Department of Pathobiology, Faculty of Veterinary Medicine, Shahid Bahonar University of Kerman, P.O. Box 7616914111, Kerman, Iran, Phone and Fax: +98 341 3222 047; E-mail: [damin@mail.uk.ac.ir](mailto:damin@mail.uk.ac.ir)

## Introduction

Cellulitis has emerged as an economically important disease syndrome of broiler chickens. Cellulitis is typified by the presence of subcutaneous fibrinonecrotic plaques and inflammation of the overlying skin (JEFFREY et al., 1999). Various agents such as *Escherichia coli*, *Pasteurella multocida*, *Pseudomonas aeruginosa*, *Enterobacter agglomerans*, *Proteus* spp., *Staphylococcus aureus*, *Streptococcus dysgalactiae* and *Arcanobacterium pyogenes* (*Corynebacterium pyogenes*) were isolated from cellulitis lesions (DERAKHSHANFAR and GHANBARPOUR, 2002). Although purulent synovitis and cellulitis due to *Erysipelothrix rhusiopathiae* in 2-day-old poult have been reported (HOLLIFIELD et al., 2000), the ability of *E. rhusiopathiae* isolates recovered from sick birds in reproduction of cellulitis is not known. The present study was therefore undertaken in order to clarify the ability of these isolates for induction of avian cellulitis.

## Materials and methods

**Bacteria.** A 52-day-old turkey cock with the signs of septicaemia was submitted to the clinic for diagnostic procedures. The patient was droopy and with unsteady gait prior to death. Necropsy findings included: swollen discoloured turgid snood, emaciation, generalized congestion, friable and enlarged liver, spleen and kidney, petechial haemorrhages in abdominal wall, and heart and skin lesions. Histopathologic examinations revealed generalized engorgement of blood vessels and sinusoidal channels in all organs, oedema in lung, haemorrhage in heart, and necrosis in liver and spleen. Necrosis and heterophilic infiltration with fibrinous exudates was obvious in the skin. Confirmation of erysipelas was achieved by demonstration of *E. rhusiopathiae* as gram-positive rods in liver, spleen, heart blood and bone marrow smears. Bacteriological samples from liver, spleen, heart blood and bone marrow were cultured with isolation of *E. rhusiopathiae* (QUINN et al., 1994).

**Experiment.** The study involved two experimental groups, each consisting of twenty randomly selected 15-day-old, mixed sex, healthy, commercially grown broiler chickens of the same strain. A single scratch was induced with a 1.5 inch 18-gauge needle, creating a lesion 2 cm in

length on the right dorsolateral surface of the body parallel to the vertebrae in each bird. The site of the scratch was disinfected by swabbing with 70% ethanol, which was then allowed to dry. In Group 1, 1 ml of 10% bacterial suspension was inoculated into the scratches using a 1.5 inch, 18-gauge needle. Birds in Group 2 received 1ml of the sterile phosphate-buffered saline (PBS) as negative controls. The chickens were fed commercial broiler starter rations and had unrestricted access to water.

*Pathology.* At 48 hr post-inoculation birds were killed by cervical dislocation, and skin samples were obtained. Samples were fixed in 10% phosphate-buffered formalin, dehydrated in ethanol, cleared in Xylene, embedded in paraffin, sectioned at 5  $\mu$ m, and stained with hematoxylin and eosin. Post-mortem examination of dead birds - in Group 1 - was performed and samples from their heart, spleen, kidney, liver and skin were prepared in the same manner.

*Bacteriology.* Isolation of bacteria from the site of injection, liver, spleen, heart blood and bone marrow were made by culturing samples on blood agar and MacConkey agar (Biolife Laboratories, Italy).

Liver, spleen, heart blood and bone marrow smear were obtained from both killed and dead birds and stained using Gram and Giemsa methods.

## Results

*Observations.* Birds in the control group were normal during the period of the experiment. Mild swelling and hyperaemia at the site of injection was obvious. Birds in the other group showed signs of weakness, depression and mild diarrhoea. In this group, 7 (35%) birds died within 24 hrs post-inoculation, with swelling and discoloration at the site of injection. Changes were prominent at the site of injection in the remaining 13 birds at the end of the experiment (Fig. 1).

*Gross pathology.* There was no sign of any abnormality in the control group. Skin and underlying muscle was hyperaemic, with no exudation or inflammation in this group. Dead birds in Group 1 showed congestion of the liver, spleen and heart. Although thickening and discoloration at the site of injection was obvious, exudation was minimal. The thirteen remaining birds in Group 1 showed severe swelling and exudation beneath

the skin, with a moderate amount of fibrin. Gross changes in internal organs were the same as seen in the dead birds.

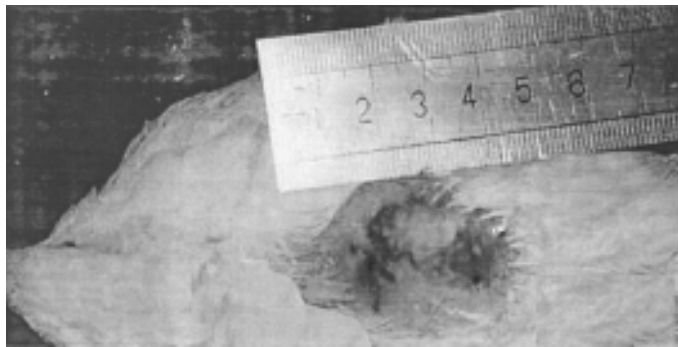


Fig. 1. Swollen, white discoloured skin of a 15-day-old broiler chicken with experimental *E. rhusiopathiae* cellulitis

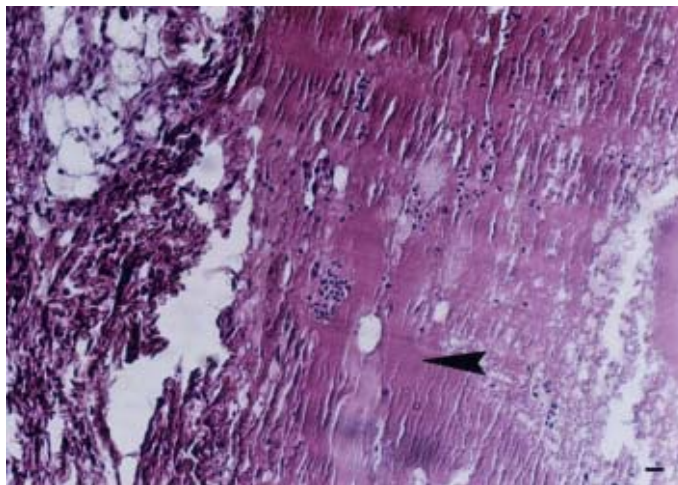


Fig. 2. Subcutis of a 15-day-old broiler chicken. Note the marked fibrinous exudate (arrowhead) and infiltration of heterophils. H&E, scale bar = 300  $\mu$ m.

*Histopathology.* None of the control birds developed cellulitis. Dead birds in Group 1 showed mild cellulitis with infiltration of heterophils. Thirteen birds with gross changes of cellulitis in Group 1 revealed severe cellulitis with necrosis, infiltration of heterophils and fibrinous exudation (Fig. 2). Birds in Group 1 showed severe hyperaemia in all organs, necrosis in liver and spleen and haemorrhage in heart.

*Bacteriology.* Bacteria were recovered from skin, liver, spleen, heart blood and bone marrow in Group 1 birds. These organisms were demonstrated in liver, heart blood and bone marrow smears. Bacterial isolation was not successful in the control group.

### **Discussion**

Erysipelas has been reported in many different vertebrate species. In birds, it generally causes an acute, fulminating infection of individuals within a flock. Outbreaks of erysipelas in turkeys, chickens, pheasants, duck, geese, guinea fowl, Coturnix quail and chukars have been reported (CALNEK et al., 1997). Although, erysipelas-induced skin lesions have been reported previously (BICKFORD et al., 1978; HOLLIFIELD et al., 2000), experimental cellulitis due to a causative agent of the disease has not been performed. Turkeys, chickens and other avian species are susceptible to infection with *E. rhusiopathiae* experimentally. In this manner, administration of the pathogen parentally, intrapalpebral or subconjunctival along with injury to that tissue could result in septicaemia (CALNEK et al., 1997). Other observations have suggested that any insult to the integrity of the skin, regardless of when it occurs, should be considered a significant route of cellulitis pathogenesis (NORTON et al., 1999; PEIGHAMBARI et al., 1995). Cannibalism and fighting among birds and mechanical transmission of *E. rhusiopathiae* by biting flies result in increased incidence of the disease. Areas previously contaminated with faeces from pigs or sheep with erysipelas, fish meal and fish have been cited as probable sources of infection for avian species (CALNEK et al., 1997). Although egg transmission of *E. rhusiopathiae* has not been described, this organism was isolated from the yolk sac. Another portal of entry could have been the still unhealed navel (HOLLIFIELD et al., 2000). Soil is known to harbour the organism for long periods, and swine and sheep, as well as various species of wild life,

can harbour the organism (CALNEK et al., 1997). Tracing the infection to chicken-raising premises has proved that the bacterium was present in some of the chickens and manure samples (SALAMAH, 1988). Genetic resistance may play a role in susceptibility to disease (CALNEK et al., 1997). Some reports support the probable transmission of disease as localized inflammation to workers' fingers at the processing plant (MUTALIB et al., 1995). Cellulitis was categorized in to two groups. Cellulitis with unopened skin lesions (Type A) and cellulitis with open skin lesions (Type B) (GOMIS et al., 1997). Although in the present study the lesions were reproduced by scratching the skin, within 24 hrs post-inoculation the site of inoculation was seen as an unopened lesion. It was suggested that steps to reduce the opportunity for trauma to the skin should significantly lower the occurrence of avian cellulitis (PEIGHAMBARI et al., 1995). Some reports confirmed that scratches were required for the induction of avian cellulitis. They suggested that naturally occurring dermal scratches may be sufficiently small, or healed to the point of being overlooked, when observing cellulitis lesions (NORTON et al., 1997). Previously *E. coli* cellulitis was reproduced by injection of inoculum to subcutaneous layers (NORTON et al., 1997), or by swabbing the scratches with contaminated swabs (PEIGHAMBARI et al., 1995). In the present study, injection of inoculum into the scratch prevented the leakage and contamination, and produced a condition similar to naturally occurring cellulitis. In experimental erysipelas in turkeys, heterophil and mononuclear leukocytic infiltration were observed in scarified skin (BICKFORD et al., 1978), but there was no sign of fibrinonecrotic exudate, which is accepted as the characteristic feature of cellulitis (CALNEK et al., 1997). In the present study, 35% of the bacterially inoculated birds died. Previous findings have proved that the bacteria entering through the skin sometimes find their way into the blood circulation and caused septicaemia (PEIGHAMBARI et al., 1995). In conclusion, it seems that prior to death, some birds may pass through the cellulitis phase. Accordingly, *E. rhusiopathiae* can be considered as a causative agent of avian cellulitis, with public health hazards.

---

#### Acknowledgments

We wish to acknowledge the kind cooperation of Dr. M.M. Oloumi in the preparation of photographs.

### References

- BICKFORD, A. A., R. E. CORSTVET, A. S. ROSENWALD (1978): Pathology of experimental erysipelas in turkeys. *Avian Dis.* 22, 503-518.
- CALNEK, B. W., H. JOHN BARNES, C. W. BEARD, L. R. MCDUGALD, Y. M. SAIF (1997): *Diseases of poultry*. 10<sup>th</sup>ed, Mosby-Wolfe, London, pp. 247-255.
- DERAKHSHANFAR, A., R. GHANBARPOUR (2002): A study on avian cellulitis in broiler chickens. *Vet. arhiv* 72, 277-284.
- GOMIS, S. M., T. WATTS, C. RIDDELL, A. A. POTTER, B. J. ALLAN (1997): Experimental reproduction of *Escherichia coli* cellulitis and septicemia in broiler chickens. *Avian Dis.* 41, 234-240.
- HOLLIFIELD, J. L., G. L. COOPER, B. R. CHARLTON (2000): An outbreak of erysipelas in 2-day-old poults. *Avian Dis.* 44, 721-724.
- JEFFREY, J. S., R. P. CHIN, R. S. SINGER (1999): Assessing cellulitis pathogenicity of *Escherichia coli* isolates in broiler chickens assessed by an in vivo inoculation model. *Avian Dis.* 43, 491-496.
- MUTALIB, A., R. KEIRS, F. AUSTIN (1995): Erysipelas in quail and suspected erysipeloid in processing plant employees. *Avian Dis.* 39, 191-193.
- NORTON, R. A., S. F. BILGILI, B. C. MCMURTREY (1997): A reproducible model for the induction of avian cellulitis in broiler chickens. *Avian Dis.* 41, 422-428.
- NORTON, R. A., K. S. MACKLIN, B. C. MC MUTREY (1999): Evaluation of scratches as an essential element in the development of avian cellulitis in broiler chickens. *Avian Dis.* 43, 320-325.
- PEIGHAMBARI, S. M., R. J. JULIAN, J. P. VAILLANCOURT, C. L. GYLES (1995): *Escherichia coli* cellulitis: experimental infections in broiler chickens. *Avian Dis.* 39, 125-134.
- QUINN, P. J., M. E. CARTER, B. K. MARKEY, G. R. CARTER (1994): *Clinical Veterinary Microbiology*. 1<sup>st</sup> ed., Wolfe Publishing, London, pp. 175-177.
- SALAMAH, A. A. (1988): Isolation of *Erysipelothrix rhusiopathiae* from a 55 years old man and a positive tracing of the infection to chicken-raising premise. *Microbiologica* 11, 169-171.

Received: 18 June 2003

Accepted: 4 May 2004

---

**DERAKHSHANFAR, A., R. GHANBARPOUR, S. YAZDANI: Istraživanje patoloških promjena kod celulitisa uzrokovanog bakterijom *Erysipelothrix rhusiopathiae* u pokusno zaraženih tovnih pilića. Vet. arhiv 74, 217-224, 2004.**

**SAŽETAK**

Celulitis peradi ozbiljan je problem u proizvodnji tovnih pilića. Iako su različiti agensi izdvojeni iz celulitičnih lezija, sposobnost *Erysipelothrix rhusiopathiae* u izazivanju celulitisa nije poznata. Stoga je cilj ovog istraživanja bio istražiti ulogu ove bakterije u nastanku celulitisa peradi. Korištene su dvije pokusne skupine, od kojih je svaka bila sastavljena od nasumce odabranih dvadeset komercijalno uzgajanih, zdravih, petnaestodnevni tovnih pilića, mješovita spolnog sastava i istog soja. Na desnoj dorzolateralnoj strani tijela paralelno s kralježnicom, iglom je načinjena ogrebotina duga 2 cm. Pilićima jedne skupine u tu je ogrebotinu inokuliran 1 ml suspenzije s  $10^2$  bakterijskih stanica uzročnika izdvojenog iz purana s vrbancem. Pilići druge skupine primili su 1 ml sterilne puferirane otopine fosfatne soli kao negativnu kontrolu. Pilići su bili žrtvovani 48 sati nakon inokulacije, a potom su načinjena patološka i bakteriološka istraživanja. U 65% pilića iz prve skupine uočeno je otečenje kože s nekrozama, infiltracija heterofila i fibrinozni eksudat, što je osebujno za celulitis. Preostalih 35% pilića je uginulo unutar 24 sata nakon inokulacije sa znakovima blagog celulitisa. *Erysipelothrix rhusiopathiae* bio je ustanovljen u koži i nekim unutarnjim organima pilića iz prve skupine. Pilići iz druge skupine bili su zdravi. Rezultati ovog istraživanja pokazuju da se *E. rhusiopathiae* može smatrati uzročnikom celulitisa peradi i predstavlja opasnost za javno zdravstvo.

**Ključne riječi:** *Erysipelothrix rhusiopathiae*, celulitis, tovni pilići, vrbanc

---